Phase Contrast MRI: Development of a User-Friendly Platform for Fast-Automated Segmentation and Fluid-Dynamic Post-Processing

S Pirola[1], F Piatti[1], F Sturla[1], E Votta[1], I Nesteruk[2], M Lombardi[3], A Della Corte[4], M Bissell[5], A Redaelli[1], EG Caiani[1]

[1]DEIB, Politecnico di Milano, Milan, Italy;
[2]Institute of Hydromechanics, National Academy of Sciences of Ukraine, Kyiv, Ukraine
[3]Multimodality Cardiac Imaging Section, I.R.C.C.S., Policlinico San Donato, Milan, Italy
[4]Department of cardiothoracic and Respiratory Sciences, Second University of Naples, Naples, Italy
[5]Division of Cardiovascular Medicine, Radcliffe Department of Medicine, University of Oxford, Oxford, United Kingdom

Abstract

4D flow MRI is an established technique able to deepen the complex fluid-dynamic phenomena induced by different cardiovascular pathologies. This technique may play a key role in identifying sound fluid-dynamic markers for a prompt identification of cardiovascular pathologies. However, 4D flow is not currently used in clinical practice due to its laborious post-processing.

The present work aims at developing a dedicated platform to provide a comprehensive and user-friendly tool for 4D flow data analysis, including semi-automated segmentation, and qualitative and quantitative fluid-dynamic analyses. Segmented aortic lumen contours showed good agreement with manual tracings, by DICE, linear correlation and Bland-Altman. Preliminary analysis of 5 patients with bicuspid aortic valve (BAV) pointed out the significant impact of BAV alterations on ascending aorta fluid dynamics.

The developed tool, at the best of our knowledge, represents the first release of a comprehensive analysis framework able to promote a larger clinical applicability of the 4D flow technique.

1. Introduction

3D Phase Contrast MRI (PC MRI) – also addressed as 4D flow – is an established technique able to provide blood flow *in vivo* assessment by the acquisition of MRI images complemented by three modulated gradients inducing phase offsets between $\pm\pi$ to moving protons [1]. Their motion is then encoded into velocity data along three orthogonal directions, thus generating a full 4D velocity-map (3D spatial + 1D time) of the specific anatomical volume of interest. 4D flow has been recently adopted to deepen the complex fluid-dynamic phenomena induced by different cardiovascular pathologies, e.g. bicuspid aortic valve (BAV) and total cavopulmonary connection [2]. Indeed, 4D flow may play a key role in identifying sound "haemo-dynamic markers" for a prompt identification of cardiovascular pathologies through the extraction of several haemo-dynamic variables: flow rate, vorticity, helicity, pressure-maps, wall shear stress [2]. Nevertheless, 4D flow is not used in daily clinical practice, mostly likely due to its laborious post-processing.

To overcome this limitation, our aims were: 1) to develop a dedicated platform, composed of a pre-processing module for fast and semi-automated aortic lumen segmentation and of a post-processing module for intuitive and real-time qualitative and quantitative 4D flow analyses; 2) to preliminary validate segmentation results with manual tracings; 3) to test the clinical applicability of the implemented platform on BAV patients.

2. Materials and methods

The tool, completely implemented in Matlab (The MathWorks Inc., Natick, MA, United States), is equipped with an user-friendly graphical user interface developed to increase the usability of the platform. The cartesian velocity components (v_x, v_y, v_z) are extracted from delta phase images along the three orthogonal directions *(x, y, z)* [1] and combined to obtain velocity magnitude images.

2.1. Segmentation module

A dedicated segmentation algorithm performing Region Growing and Thresholding (Rg-Th), was implemented based on the 4D flow image features with respect to sagittal slices of the aortic lumen. The standard deviation (SD) image is computed using a 3x3 mask

(Figure 1-B) to differentiate the lung from the aorta and surrounding tissues; on the SD image, a 2D Rg is applied to cancel the lungs (Figure 1-D); on the magnitude image, a double Th (empirically set to 0.2 and 0.9) is used on normalized videointensities to highlight pixels with reasonable velocity range (Figure 1-C).

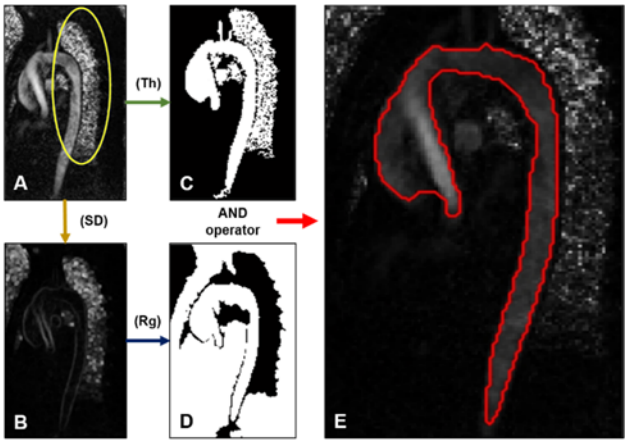

Figure 1. A) Velocity magnitude image. B) Standard Deviation image. C) Results of a double thresholding operation. D) Result of a region growing process. E) Final segmented image of the selected ROI.

These two binary masks are combined with a logical AND operator to obtain the final segmented image (Figure 1-E, in red the outline of the detected lumen). Manual interaction is required only to place around five seeds in every slice of interest used for the Rg step.

Segmentation results by Rg-Th algorithm were validated on two 4D flow MRI datasets (S01 and S02), composed by 25 and 27 images, respectively, where the aortic lumen was manually segmented by two expert operators (OpA and OpB) in a blinded fashion. The 3D DICE similarity coefficient was computed vs both OpA and OpB tracings, and between OpA and OpB to assess gold standard variability. In addition, the Rg-Th lumen area for each slice was compared with the mean area of (OpA, OpB) by linear correlation and Bland-Altman analyses.

2.2. Post-processing module

First, the centerline of the detected lumen is automatically extracted using an *ad-hoc* algorithm that computes the centroid in cross-sectional planes and then interpolates them with a natural cubic spline. Then, after manual placement of a "seed" inside the vessel, the cut-plane normal to the centerline direction is defined and the following fluid-dynamic and morphological variables are computed: i) velocity vectors; ii) lumen area, A; iii) blood flow rate, Q; iv) flow displacement, FD [3]; v) flow jet angle, FJA [3]; vi) local normalized helicity, LNH [4]; vii) wall shear stress (WSS), calculated from the complete formulation of the Newtonian model and projected on the tangential plane to ensure that the estimated WSS vector is tangential to the vessel wall [5]. The total strain tensor was obtained using 3D Sobel filters.

2.3. Clinical population

Five patients with BAV were enrolled. 4D flow acquisitions were performed at John Radcliffe Hospital (Oxford, United Kindom) on a 3.0T MR system (Trio, Siemens, Erlangen, Germany) using the protocol detailed in [6]. The Institutional Review Board approved the study and informed consent was obtained from each patient. For each dataset, segmentation was performed using the Rg-Th algorithm at peak systole. The above mentioned haemo-dynamic parameters were extracted for four characteristic planes on the ascending aorta: supravalvular (P1); sinotubular junction (STJ) region (P2); between the STJ and the beginning of the aortic arch (P3); distal part of the ascending aorta positioned proximally with respect to supra-aortic branches (P4).

3. Results

3.1. Segmentation validation

Figure 2-A shows overimposed the contours from OpA and OpB, together with the result of the Rg-Th algorithm on a selected slice: good correspondence of the lumen contours is appreciable. The 3D DICE similarity

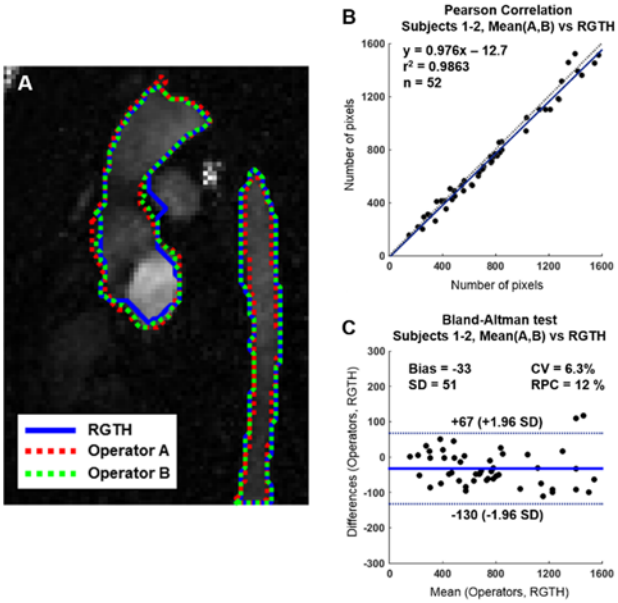

Figure 2. A) Qualitative comparison of the manual and automatic segmentations; B) Linear correlation and C) Bland-Altman plot with results of validation.

coefficient, for patients S01 and S02, respectively, was high (vs OpA: 0.91 and 0.93; vs OpB: 0.97 and 0.98) and similar to manual tracing variability (3D DICE OpA vs OpB, 0.94 and 0.95). High correlation (Figure 2-B) was found for lumen area (r^2 =0.986), with a small bias (-33 pixels) and narrow limits of agreement (Figure 2-C).

3.2. Clinical analysis

An example (patient S05) of the clinical report generated by the described platform is shown in Figure 3, where quantitative charts and qualitative plots are displayed referring to the cut-plane 3.

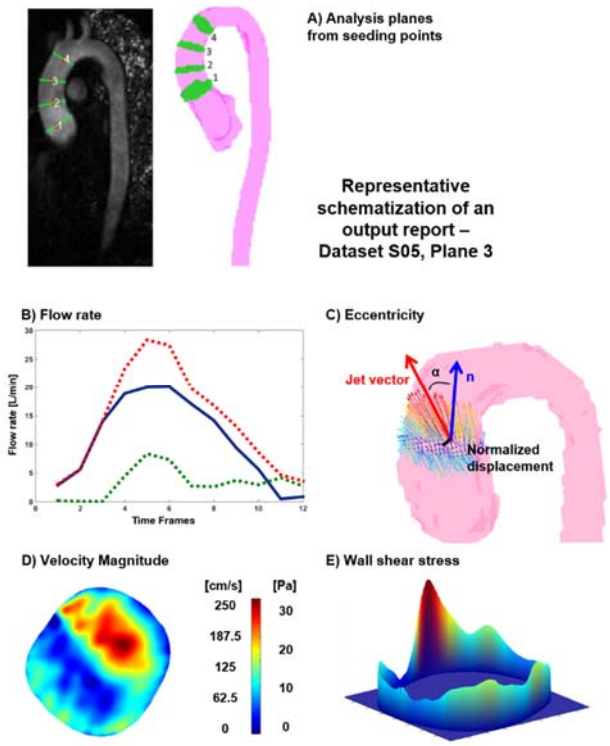

Figure 3. Representation of a schematic report: A) Cut-planes selected for analysis (P1-P4) on segmented aorta; B) Flow rate waveforms; C) Velocity vectors and eccentricity; D) 2D velocity contour; E) Wall shear stress distribution.

In Table 1, the median and range values of the computed parameters extracted from the five BAV patients are reported in detail.

The analysis of the velocity field on the four selected planes showed a high variability in V_{MAX} among BAV subjects: this is in agreement with the presence of different degrees of BAV severities. For patient S04, in particular, a narrowing of the orifice valve was clearly observed, with an area corresponding to the 25% of the lumen area, and a consequent increase of the peak velocity value. Overall, in all patients a markedly asymmetrical velocity distribution was depicted, with retrograde flows and high velocity values (Figure 3-D). The analysis of morphological data showed for patient S04, a lumen area markedly above the physiological values [7], corresponding to an equivalent median diameter of 3.8 cm (3.6 cm÷4.4 cm). In addition, all the subjects presented high variability in lumen area among the four planes.

Table 1. Quantitative representation of the extracted variables for the five datasets. Values are represented as Median (med) and Range (min – max)

	S01	S02	S03	S04	S05
			V_{MAX} [cm/s]		
med	173.9	205.3	308.1	325.5	321.3
min	214.0	223.9	372.6	360.3	410.4
max	156.7	176.4	225.7	216.7	168.3
			Lumen Area [mm^2]		
med	577	606	902	1122	690
min	402	530	867	1028	601
max	764	680	991	1531	822
			Flow Rate [l/min]		
med	19.7	28.7	22.8	31.4	19.0
min	18.6	25.2	20.1	19.4	17.0
max	21.8	31.0	25.6	33.7	20.0
			FD [-]		
med	0.20	0.18	0.24	0.17	0.21
min	0.16	0.14	0.12	0.11	0.27
max	0.20	0.20	0.28	0.19	0.17
			FJA [°]		
med	27.1	12.9	15.7	32.0	21.2
min	5.7	7.5	7.9	11.5	3.3
max	33.1	24.2	39.0	50.2	31.4
			LNH [-]		
med	0.08	0.02	0.00	-0.05	-0.10
min	-0.19	-0.16	-0.06	-0.12	-0.26
max	0.16	0.13	0.17	0.07	0.18
			WSS_{MAX} [Pa]		
med	17.41	21.58	31.11	24.62	31.68
min	13.68	16.10	21.49	19.66	37.83
max	18.91	24.52	45.43	27.86	17.83

The observed flow rates were coherent with literature data [5] and their waveforms, as shown in Figure 3-B, confirmed the presence of significant retrograde flows. As observed in Figure 3-C, which shows the eccentricity data of subject S05 (FD = 0.20 and FJA = 31.4°), a marked offset between the center of velocity and the lumen centroid characterized the systolic jet, generally deflected with respect to plane normal. This deflection, combined with altered values of velocity, causes the systolic jet to hit a reduced portion of the vessel wall on which high local values of WSS were observed. In fact, the WSS distribution (Figure 3-E) presented asymmetric peaks along the wall.

4. Discussion

To the best of our knowledge, the developed Matlab-based tool represents the first attempt to provide clinicians with a user-friendly platform for 4D flow MRI data analysis, including aortic lumen segmentation, and state-of-art computation of haemo-dynamic parameters.

The segmentation module was based on a novel semi-automated segmentation algorithm (Rg-Th) which requires only the placement of some seed points. Its validation on two of the acquired datasets compared to manual tracings showed a high agreement in 2D lumen areas for each plane. Moreover, the DICE similarity coefficient, applied directly to the 3D surfaces generated from the 2D contours, showed similar results than the comparison of the two manual segmentations.

Preliminary tests were conducted on five BAV-affected patients to point out the significant impact of the pathologic alterations on the ascending aorta fluid dynamics. From a morphological standpoint, the high area variability among the four planes might be an indicator of pathological dilatation in the ascending aorta, often noticed in BAV patients [7]. The velocity field resulted decentralized and deflected compared to both the lumen centroid and the normal plane, where the computed median values of FD and FJA resulted in agreement with previously reported mean values [3]. High velocity systolic jets were observed to hit limited portion of the vessel wall, resulting in WSS asymmetric values along the ascending aorta, in accordance with Faggiano et al [8]. The extracted flow rate values showed an inter-plane oscillation, mainly due to partial volume effects and segmentation imprecisions. The implemented algorithm for WSS assessment was based on the complete wall shear stress formulation and did not introduce any kind of simplification in the parameter extraction. However, an additional validation of the algorithm will be addressed in future studies, in order to evaluate the influence of the image spatial resolution and quantify eventual overstatement in the observed values due to the gain characteristics of the exploited filters. In any case, we confidently expect no significant alterations in the asymmetrical WSS distribution along the vessel wall, suggesting that even if an exact measurement of absolute WSS values *in vivo* remains challenging, the measured WSS distribution could be able to discriminate between pathological and physiological conditions [5].

5. Conclusions

We developed a comprehensive and easy-to-use analysis tool potentially able to promote wider clinical utilization of 4D flow MRI technique in order to deepen aortic fluid dynamics. Preliminary validation with manual tracings showed the good performance of the proposed aortic lumen segmentation method, at the basis of fluid-dynamic parameters computation. This kind of analysis may help in elucidating the effects of BAV on aortic vessel pathophysiology, thus providing multiple parameters that could be used for effective stratification of different degrees of BAV severity.

Acknowledgments

This work was supported by the Italian Health Ministry Grant (GR 2009-1580439), the British Heart Foundation and the EU-financed project EUMLS (EU-Ukrainian Mathematicians for Life Sciences) - grant agreement PIRSES-GA-2011-295164-EUMLS.

References

[1] Bernstein MA, King KF, Zhou XJ. Handbook of MRI Pulse Sequences. Elsevier, 2004.

[2] Hope MD, Sedlic T, Dyverfeldt P. Cardiothoracic magnetic resonance flow imaging. J Thorac Imag. 2013;28(4):217-30.

[3] Sigovan M, Hope MD, Dyverfeldt P, Saloner D. Comparison of four-dimensional flow parameters for quantification of flow eccentricity in the ascending aorta. JMRI, 2011;34(5):1226-1230.

[4] Morbiducci U, Ponzini R, Rizzo G, Cadioli M, Esposito A, De Cobelli F, Del Maschio A, Montevecchi FM, Redaelli A. In vivo quantification of helical blood flow in human aorta by time-resolved three-dimensional cine phase contrast magnetic resonance imaging. Ann Biomed Eng, 2009;37(3):516-531.

[5] Stalder AF, Russe MF, Frydrychowicz A, Bock J, Hennig J, Markl M. Quantitative 2d and 3d phase contrast MRI:optimized analysis of blood flow and vessel wall parameters. Magn Reson Med, 2008;60(5):1218-1231.

[6] Bissell MM, Hess AT, Biasiolli L, Glaze SJ, Loudon M, Pitcher A, Davis A, Prendergast B, Markl M, Barker AJ, Neubauer S, Myerson SG. Aortic dilation in bicuspid aortic valve disease:flow pattern is a major contributor and differs with valve fusion type. Circ Cardiovasc Imag, 2013;6(4):499-507.

[7] Kiefer A, Wang G, Hughes C, Bashore TM. Management of patients with bicuspid aortic valve disease. Curr Treat Option Cardiovasc Med,2011;13(6):489-505.

[8] Faggiano E, Antiga L, Puppini G, Quarteroni A, Luciani GB, Vergara C. Helical flows and asymmetry of blood jet in dilated ascending aorta with normally functioning bicuspid valve. Biomech Model Mechan,2013;12(4):801-813.

Address for correspondence.

Selene Pirola
Politecnico di Milano
Piazza Leonardo da Vinci 32
20133, Milan, Italy
selene.pirola@mail.polimi.it