

A Poincare Image Based detector of ECG Segments containing Atrial and Ventricular Beats

Guadalupe García-Isla, Luca Mainardi, Valentina Corino

Politecnico di Milano
Milano, Italy

An electrocardiogram (ECG) classifier for the detection of ECG segments containing atrial or ventricular (A/V) beats could ease the detection of premature atrial complexes (PACs) and by so, the study of their relationship with atrial fibrillation (AF) and stroke. In this work such a classifier is presented based on convolutional neural networks (CNN) and the RR and dRR interval representation on Poincare Images.

Two PhysioNet open-source databases containing beat annotations for 164 ECG traces from 158 patients were used. ECG signals were divided into 30-beat segments with a 50% overlap. Each segment was then transformed into a Poincare Image using a [40x40] ms bin size. RR, dRR and both types of Poincare Images combined were evaluated as inputs to the CNN. Kruskal–Wallis statistical analysis was applied to evaluate their induced change in performance. The classification model was a CNN with 25 layers trained following a patient-wise train-test division (i.e., no patient was included both in the train and test set) in a 10-fold cross-validation.

A total of 381151 and 62142 Poincare Images were computed for normal (N) and A/V segments. The patient-wise median and interquartile range accuracy, sensitivity and positive predictive values were 97.90 (94.49 - 99.28), 96.03 (89.67 - 98.76) and 91.91 (70.87 - 99.24), respectively for RR input. No statistically significant differences in performance were found among the three types of Poincare Images input.

This work tackles the problem of beat annotation, shared among studies.

Results suggest the presented methodology can detect ECG regions containing A/V beats with high precision. This implies it could be used to reduce the workload for ECG beat annotation to study PACs and other A/V implications. In addition, it could be used in combination with automatic beat classifiers to localize misclassifications and obtain more reliable annotations.

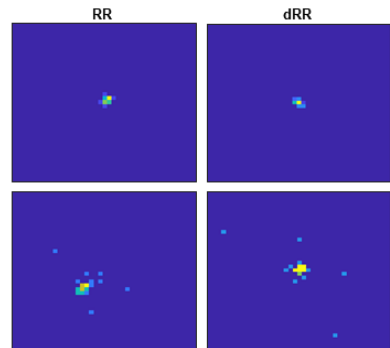


Figure 1. Poincaré Images of a normal (N) ECG segment (1st row) and A/V segment (2nd row) for RR and dRR.