

# Automatic Border Detection in IntraVascular UltraSound Images for Quantitative Measurements of the Vessel, Lumen and Stent Parameters

J Dijkstra, G Koning, JC Tuinenburg, PV Oemrawsingh, JHC Reiber

Leiden University Medical Center, Leiden, The Netherlands

## Abstract

*The automated segmentation of lumen, vessel and stent boundaries in IntraVascular UltraSound (IVUS) images will reduce the required analysis time and the subjectivity of the commonly used manual tracing procedure while the three-dimensional reconstruction permits an advanced assessment of the morphology. We describe a knowledge and model guided system for the (semi-) automatic contour detection of these borders. The different steps of a complete analysis of an IVUS pullback sequence are carried out such, that the different components assist each other. The stent detection assists the vessel detection and both detections assist the lumen detection. The results of the detection show a very good correlation with manually drawn contours. Due to the flexible use of more than two longitudinal cutplanes and the advanced knowledge-guided contour detection approach, the new IVUS analysis system has proven to be suitable for clinical research studies.*

## 1. Introduction

IntraVascular UltraSound (IVUS) is a catheter-based technique, which provides real-time high-resolution tomographic images of both the lumen and the arterial wall. Nowadays the IVUS imaging technique is used very often to assess the results of the stent placement, to

visualize and quantify the in-stent restenosis, or to assess the plaque symmetry for directional atherectomy or brachytherapy [1, 2]. In the current clinical use of IVUS, the lumen and arterial wall of a particular coronary segment are inspected visually by manually moving the ultrasound catheter through the vessel. The global positioning of the catheter is guided by X-ray angiography. In this way the section with the narrowest lumen can be selected and analyzed quantitatively by using a manual caliper in its simplest approach or by outlining the lumen and vessel wall borders in a more accurate approach. This will result in the calculation of the percent cross-sectional area narrowing at that particular cross-section, and the minimum and maximum diameters. The inter- and intra-observer variability for these measurements has been studied widely and is high [3, 4]. Furthermore, manual analysis of the images is tedious and time consuming. Nowadays, the creation a pullback image series using a motorized pullback device is becoming more common, which results in image runs of several hundreds of slices.

With the continuing improvement in IVUS imaging, it is now feasible to develop and clinically apply automated methods of three-dimensional quantitative analysis of the coronary artery wall, stent and plaque [5, 6]. The automated segmentation of lumen, vessel and stent boundaries will reduce the required analysis time and the subjectivity of the manual tracing. The defined distance between the slices with the motorized pullback devices




Figure 1. Schematic overview of stent border detection

allows the creation of longitudinal cross-sections, which provide a fast and comprehensive overview of the entire pull back sequence. Newer acquisition devices already support this option on-line.

Modern computer equipment allows the visualization and analysis of more than one pullback image series at the same time, which is very useful for the comparison of the same vessel segment at different acquisition moments e.g. pre-intervention, post-intervention and follow-up. For the selection of the identical vessel segments in the different runs, the three-dimensional reconstruction is very useful. It also makes it easier to compare the runs to angiograms, because the anatomical landmarks can be found easily by walking through the longitudinal images.

## 2. Methods

The (semi-)automated method as developed in Leiden is based on a combination of transversal and longitudinal contour detection techniques and uses models of the vessels and knowledge about the morphologic structures, the ultrasound catheter properties and ultrasound specific artifacts. From the pullback image series, a user-defined number of longitudinal cross-sections are created (usually 16). In these cross-sections the user defines the different segments for the analysis, e.g. a stent segment, a distal segment, and a proximal segment as reference.

### 2.1. Transversal stent detection

The stent contour detection is performed in the transversal slices in the defined segment and is carried out in two steps. The first step is the global estimation of the location of the struts. Therefore the image is polar transformed using the catheter as the center. Next, a so-called cost matrix is created. Each element in this matrix is filled with a value based on a combination of the intensity of the corresponding pixel and the distance towards the catheter. The weight factors are based on the fact that the stent struts generally have a higher intensity than the surrounding tissue (Fig. 1a) and it is more likely that bright stent struts are located closer to the catheter than calcified spots. This distance compensation depends on the depth and gain settings of the acquisition system and the presence of in-stent restenosis. Using the Minimum Cost Algorithm (MCA), candidate points are identified to create a model for the second, more locally directed, detection of the strut location (Fig. 1b). The image is resampled according to the new model. This second detection uses the approximately circular shape of the stent and image gradient perpendicular to the model, taking into account that the strut is bright. The results can be seen in Figure 1c. The stent detection can correct itself based on a 3D model in which the change in size and position of the stent contour is limited over a short distance. Even in slices with poorly defined stent struts, a meaningful stent contour can be found in this way. It

should be noted that in situations such as direct stenting, large differences in diameter might exist over the entire length of the stent.

The stent detection is performed only in the transversal images, because the appearance of the stent struts is much less regular in the longitudinal cross-sections, and in some cross-sections no struts are visible at all. Therefore, applying continuity criteria is much more difficult.

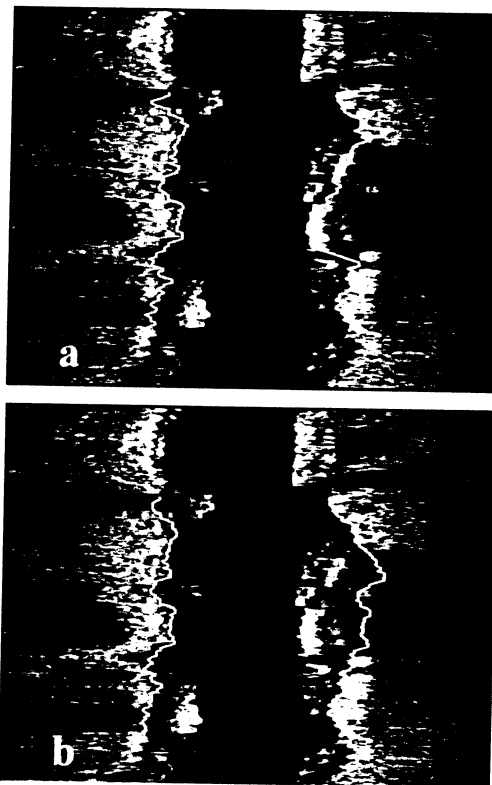


Figure 2. Single (a) and simultaneous (b) longitudinal vessel detection

### 2.2. Longitudinal vessel detection

In a number of the longitudinal cross-sections, the vessel contours are detected *simultaneously* which means that they have knowledge about each other's position. For example, the following situation may occur. At one side of the vessel in the longitudinal image, a clear vessel transition is present which would force the vessel contour detection to the left. On the other side of the vessel, multiple potentially vague vessel transitions in different directions are present. The simultaneous technique will now select the combination of the strong transition at one side, and a transition on the other side, which matches best with the morphologic continuity of the vessel and the shape and size of the vessel. This technique is especially useful for regions behind of calcified plaque and in side branches where no or sparse image information is available to support the contour detection. Figure 2 shows an example in which the vessel contours are detected

separately and simultaneously. The improvement can be clearly seen at the right vessel contour behind the calcified plaque. If a stent is present, the vessel contour will also be forced outside the already detected stent.

### 2.3. Longitudinal lumen detection

The lumen contours are detected in the same longitudinal images as the vessel contours. The detection is based on the location of the catheter, the already detected vessel contour, and gradient information from the image. The lumen-intima border is the first more or less continuous edge seen from the catheter. A simultaneous detection for the lumen is not meaningful since the shape can be much more irregular. A rough tissue classification based on gray value and texture, supports the contour detection in areas where the catheter is located against the wall and no lumen can be distinguished. If a stent is present, the lumen border can optionally be forced inside the stent border. In case of incomplete stent expansion it should be possible to define the lumen contour outside the stent contour.

### 2.4. Transversal detection

For each longitudinal contour, the corresponding points in the transversal images are calculated, resulting in attraction points for the transversal contour detection. The contour detection in the transversal images is guided by these attraction points, but not forced, which has the advantages that some errors in the longitudinal contour detection can be overruled by the transversal contour detection. If necessary, these attraction points can be selected by the user for correction. The corrections will be applied both in the transversal and the longitudinal images, which makes the user-interaction procedure more efficient. The stent restrictions, which were used for the longitudinal contour detection, are also used for the transversal contour detection. These restrictions improve

the border detection since the stent struts will attract the vessel and lumen contour detection.

Based on all the contour data, the derived parameters are calculated over the defined segments. Figure 3 shows an example how an output graph may look like. In this example also a distal and a proximal segment have been defined so that the vascular remodeling in the stented segment can be demonstrated.

## 3. Results

To assess the accuracy of the contour detection techniques, experts manually did draw the vessel and lumen borders in a set of 240 randomly selected slices from different in-vivo pullback sequences acquired by different ultrasound systems (Boston Scientific and EndoSonics). In these series the different borders were also detected automatically by the software over an entire segment. The cross-sectional vessel and lumen areas circumscribed by the borders of both the manually traced and automatic detected borders in the corresponding slices were compared and resulted in correlation coefficients of 0.99 and 0.98, respectively. Most problems for the vessel contour still occur in areas behind calcified plaque due to different interpretations by experts. For the lumen contour very weak interfaces may result in a difference in interpretation between experts or between the experts and the software.

In another set of in-vivo pullback runs, both post-intervention and follow-up, the automatically detected stent boundaries in 120 slices were compared to the manually drawn stent boundaries and resulted in a correlation coefficient of 0.99. It should be noted that for the automatic detection at least three struts have to be visible in the image, but this is also true for the expert. In some cases no struts were visible at all due to the catheter orientation, while they should be present based on the location in the segment and the type of stent.

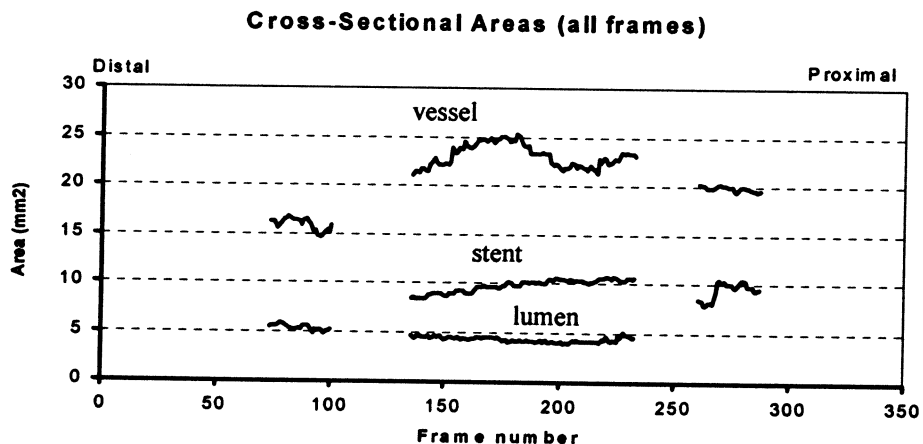


Figure 3. Example of an output graph for quantitative IVUS measurements.

Furthermore, we analyzed 14 pullback sequences of coronary vessels with obstructive coronary artery disease (acquired in-vivo). These pullback series were also analyzed with the validated analytical software on the TomTec system. The vessel and lumen areas in 877 slices determined by our system correlated well with the results of the TomTec system (r-values of 0.99 and 0.98, respectively).

#### 4. Discussion

The requirements for the automatic contour detection of IVUS images are different for the on-line application in the catheterization laboratory during a procedure, and the off-line application for clinical research and evaluation.

For the on-line application the speed of operation is much more important than the exact volumetric data from the pullback image series. Important are the location and parameters of the narrowest lumen site and the parameters of reference slices, which should be detected. This should be done with as little user-interaction as possible to speed up the process and to make it possible to perform the measurements in the cathlab by technicians or nurses with some experience with IVUS interpretation. The operating cardiologist will still be responsible for the final judgement. Extensive three-dimensional reconstruction e.g. using biplane angiograms for correct reconstruction to improve the volumetric calculation is not necessary. However, the synchronization between IVUS images and a marker in the angiograms can be useful to combine the local information from IVUS with the global information from the X-ray images.

For the off-line quantification, an accurate contour detection and correct three-dimensional reconstruction will improve the volumetric measurements [7, 8], which may be important to determine small differences in plaque volumes. However, in small segments the volumetric calculation errors due to curvature and torsion are small [9]. The speed of operation in the off-line situations is less critical and more user-interaction is allowed to correct for small miss-interpretations.

The described quantification system is able to function both on-line and off-line.

#### 5. Conclusion

Due to the flexible use of more than two longitudinal cut planes and the advanced knowledge-guided contour detection approach, the new IVUS analysis system has proven to be suitable for clinical research studies. Due to the nature of the IVUS imaging technique, which results in image artifacts and drop-out regions, there is still a need for some user-interaction, but by using efficient user-interaction which apply corrections in a three-dimensional nature, the number of corrections is quite

small. The inclusion of the automatically detected stent boundary will support in-stent restenosis studies, for instance to examine the effects of coated stents.

#### Acknowledgements

This project was supported by the Dutch Technology Foundation (NWO-Technologiestichting STW) under grant nr. LGN 3419.

#### References

- [1] Nissen SE, Yock PG Intravascular Ultrasound: Novel pathophysiological insight and current clinical applications. *Circulation* 2001;103:604-616.
- [2] Reiber JHC, Koning G, Dijkstra J, et al. Angiography and Intravascular Ultrasound. In: Sonka M, Fitzpatrick J, eds. *Handbook of Medical Imaging - Volume 2: Medical Image Processing and Analysis*. Bellingham, WA.: SPIE, 2000:711-808.
- [3] Peters RJG, Kok WEM, Rijsterborgh H, et al. Reproducibility of quantitative measurements from intracoronary ultrasound images. *European Heart Journal* 1996;17:1593-1599.
- [4] Blessing E, Hausmann D, Sturm M, Wolpers HG, Amende I, Mugge A. Intravascular ultrasound and stent implantation: Intraobserver and interobserver variability. *American Heart Journal*. Feb 1999;137(2):368-371.
- [5] Dijkstra J, Wahle A, Koning G, Reiber JHC, Sonka M. Quantitative coronary ultrasound: state of the art. In: Reiber JHC, Wall EE van der, eds. *What's new in Cardiovascular Imaging*. Dordrecht: Kluwer Academic Publishers, 1998:79-94. *Developments on Cardiovascular Medicine*; vol 207.
- [6] Von Birgelen C, Mintz GS, de Feyter PJ, et al. Reconstruction and quantification with three-dimensional intracoronary ultrasound: An update on techniques, challenges, and future directions. *European Heart Journal* 1997;18:1056-1067.
- [7] Wahle A, Prause GPM, von Birgelen C, Erbel R, Sonka M. Fusion of angiography and intravascular ultrasound in vivo: Establishing the absolute 3-D frame orientation. *IEEE Transactions On Biomedical Engineering*. Oct 1999;46(10):1176-1180.
- [8] Slager CJ, Wentzel JJ, Schuurbiens JCH, et al. True 3-dimensional reconstruction of coronary arteries in patients by fusion of angiography and IVUS (ANGUS) and its quantitative validation. *Circulation*. Aug 2000;102(5):511-516.
- [9] Schuurbiens JCH, von Birgelen C, Wentzel JJ, et al. On the IVUS plaque volume error in coronary arteries when neglecting curvature. *Ultrasound In Medicine And Biology*. Nov 2000;26(9):1403-1411.

Address for correspondence.

Jouke Dijkstra, Ph.D.  
Department of Radiology  
Leiden University Medical Center  
P.O. Box 9600 (Postzone C2-S)  
2300 RC Leiden, the Netherlands  
E-mail: jouke.dijkstra@lumc.nl