

New Markers for Diastolic Function by Cardiac Magnetic Resonance Imaging

O Grebe, M Höher, F Schwenker*, H Neumann*, J Wöhrle, G Palm*, V Hombach, HA Kestler*

Dept. of Cardiology and *Dept. of Neural Information Processing,
University of Ulm, Ulm, Germany

Abstract

Aim of the study was to test a new method to evaluate diastolic heart function by magnetic resonance imaging (MRI). 11 healthy subjects (control) and 11 consecutive patients with wall motion abnormalities and hypertension were examined with MRI. Imaging was performed on a 1.5T whole body scanner using a steady state free precession sequence. For the analysis a single mid-ventricular short axis slice in the true cardiac axis with 23 heart phases (23 frames per heart cycle) was utilized. Three types of features were applied to characterize diastolic function: (1) Slope of a linear least-squares fit to the diastolic area change (SLOPE); (2) shift parameter of the least-squares fit of the sigmoid Fermi-function (SHIFT); and (3) irregularity marker of contraction calculated as the sum of the standard deviations of corresponding points across all frames (IRREG). All markers differed significantly in both groups. We conclude that these previously unobserved features serve as objective parameters for the assessment of the diastolic left ventricular function.

1. Introduction

The full heart cycle comprises contraction (systole) and relaxation (diastole). Relaxation is as well important for global ventricular performance as systolic function but more difficult to assess. Relaxation speed and duration for example measured by echocardiography are accepted parameters for the diastolic function of the left ventricle [1]. Primary diastolic heart failure can be seen in patients with left ventricular hypertrophy (due to pressure overload as it occurs with hypertension or obstruction of the outflow tract) and restrictive cardiomyopathy. Impairment of the diastolic function is also an early sign of myocardial ischemia.

As an invasive approach, indices of passive left ventricular characteristics derived from the diastolic left ventricular pressure-volume relations can be measured. However, this method requires high cine frame rates and volume load of the injected contrast medium has to be taken into account. Non-invasive measurements obtained from echocardiography, e.g. the pattern of left ventricular

diastolic filling can be inaccurate due to methodological problems like pseudonormalization or poor sonographic quality. In addition, measurements are dependant on pre- and afterload and heart rate.

The evaluation of the heart function by magnetic resonance imaging (MRI) as a non-invasive tool with a good spatial and temporal resolution has become feasible in the last years. Current dedicated cardiovascular MRI scanners provides excellent demarcation of the endocardial border in nearly all patients. There are different approaches to determine diastolic function by MRI. Flow velocity and volume measurements across the mitral valve are possible [2] but hampered by a systemic error due to the movement of the valve plane during the heart cycle. Up to now there is lack of an easy obtainable global parameter for the assessment of diastolic heart function.

2. Methods

2.1. Subject data

Eleven healthy subjects (control) and eleven consecutive patients with a history of myocardial infarction (MI) and wall motion abnormality were examined with magnetic resonance imaging.

All of the MI patients had hypertension treated with drugs. In all of those who underwent cardiac catheterization for clinical reasons (55%) an elevated left ventricular end-diastolic pressure was confirmed.

The control group had a median age of 32 yrs (interquartile range 30 to 46 yrs), the MI group was significantly older with age 65 yrs [59;68 yrs], $p < 0.01$. The heart rate, which influences relaxation, did not differ between the MI and the control group (median 69 vs. 72 beats per minute, $U = 46.5$, $p = 0.35$).

Septal wall thickness was normal in the control group (median 10.0 mm [9;10 mm]). In the MI group all patients had significant left ventricular hypertrophy (median 14.0 mm [12.0;15.5 mm], $p < 0.01$).

2.2. Imaging

Imaging was performed on a 1.5T whole body scanner (Intera CV, Philips Medical Systems) with Master Gradients (slew rate 150 T/m/s, amplitude 30 mT/m) and

cardiac software package Intera R7.1, and a 5-element phased-array cardiac coil. Three short survey scans were performed to define the position and true axis of the left ventricle. Afterwards, wall motion was imaged during breath holding with in long and short-axis slices using a new steady-state free precession (balanced fast-field echo) sequence, which provides an excellent demarcation of the endocardium. Cardiac synchronization was achieved by prospective gating. The cine images were recorded with 23 heart phases (23 frames per heart cycle). Septal wall thickness was measured in a basal short axis slice.

2.3. Image Analysis

A single mid-ventricular short axis slice was chosen for the analysis. Short axis slices are more representative for the cardiac function than long axis views and planimetry results in a nearly circular area. In addition, partial-volume-effects are less in short-axis-slices compared to the long axis. Endocardial contours for each of the 23 heart phases were hand-drawn on a Sun Ultra 60 workstation using the Easy Vision Software Release 4.4 (Philips, Best, The Netherlands). The papillary muscles were assigned to the ventricular cavum (fig. 1). Movie sequences of the contours were then exported as MPEG files. From these image sequences the cross sectional mid-ventricular area was determined across all frames with a computer algorithm resulting in binary image sequences. On these pre-processed images three types of features were applied to characterize diastolic function: First, the slope of a linear least-squares fit to the diastolic area change (SLOPE) beginning in the frame with the minimum area. This feature characterizes the steepness and therefore the speed of the relaxation. As the second feature the shift parameter of the least-squares fit of the sigmoid Fermi-function to the diastolic area change (SHIFT) was determined. It describes the duration of mid-systole and early diastole. As a third feature an irregularity marker of contraction was calculated as the sum of the standard deviations of corresponding eight points across all frames (IRREG; Fig. 2).

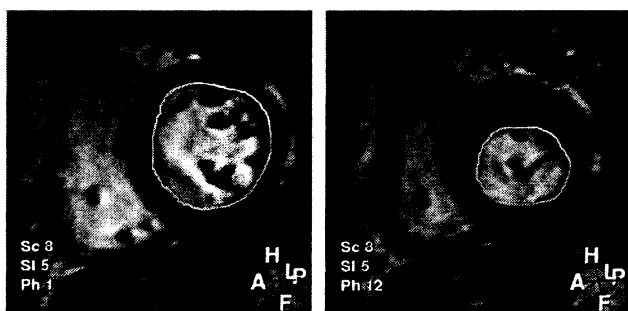


Figure 1. A MR short axis slice acquired from a patient with posterior infarction. The left image is end-diastolic, the right image mid-systolic. The hand-drawn endocardial contour is shown.

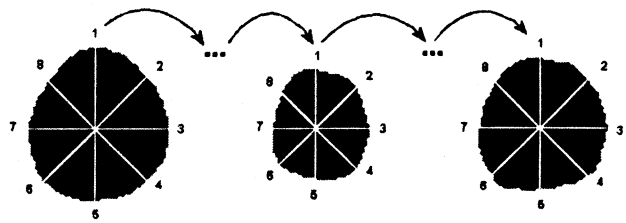


Figure 2. Illustration of the irregularity marker of contraction. The crossing point of the six lines is the center of gravity. Eight points on each frame were traced and described by their standard deviations.

2.4. Statistics

Continuous data are presented as median and interquartile ranges. For analysis of differences between groups, the Mann-Whitney U-test was used. A statistical probability of $p < 0.05$ was considered to be significant.

3. Results

Median change of the area across the heart cycle is shown on Fig. 5, individual curves for both groups is found in Figs. 3 and 4. A shift of the diastolic slice area enlargement towards later frames in the patient group can be observed in the figures. In addition the upslope appears to be more steep in the controls. The applied features confirmed this:

In the control group the median SLOPE was significantly higher compared to the MI group ($U=28$, $p=0.03$), which corresponds to a slower relaxation speed in the hypertensive MI patients. SHIFT differed significantly in both groups ($U=28$, $p=0.03$). The irregularity marker IRREG was also significantly higher in the MI group ($U=27$, $p=0.03$).

The slope of the fermi function was 0.33 [0.3;0.4] in the control group and 0.24 [0.2;0.3] in the MI group, respectively ($p=0.12$). The functions obtained from the median slope and SHIFT for both groups are shown on Fig. 6.

Median area fraction calculated as 1-min/max and corresponding to the global ventricular performance was lower in the MI group (46% vs. 52%) compared to the control group, but the difference was not significant ($U=34.0$, $p=0.08$).

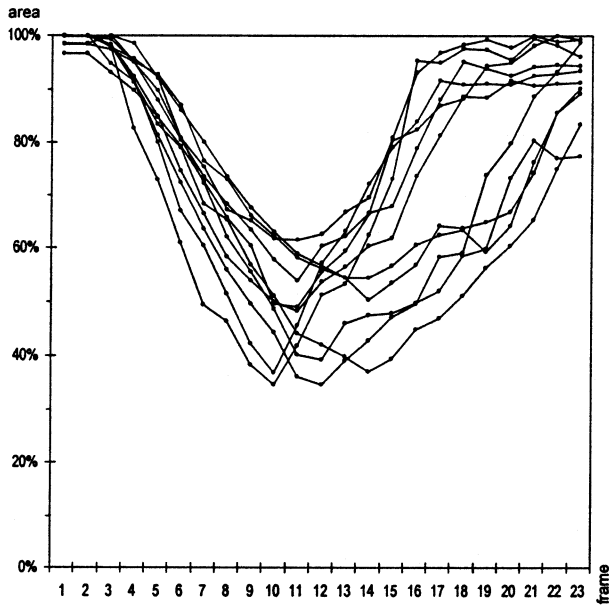


Figure 3. Changes of the slice area during the heart cycle for each control subject is shown above. The area was normalized by the maximum.

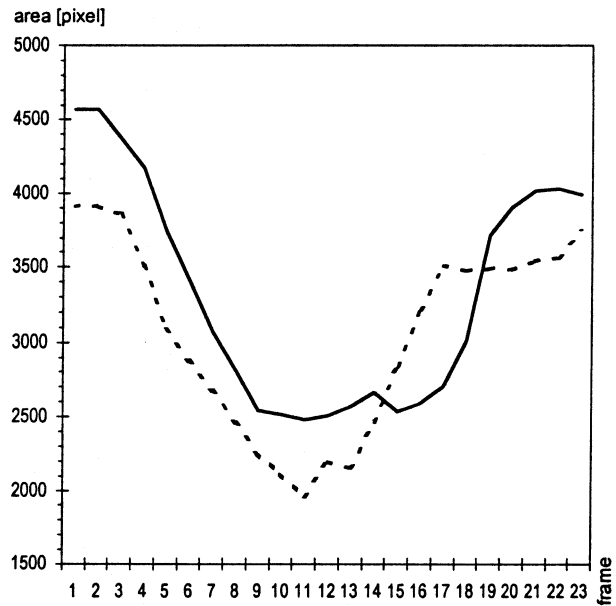


Figure 5. Median over time of the cross-sectional area in pixels of the control group (dashed line) and the hypertensive patients (solid line). There is a shift towards late heart phases in the MI group.

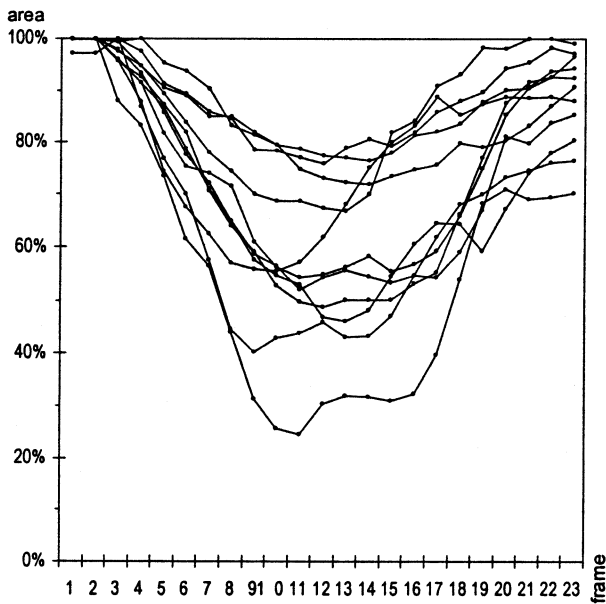


Figure 4. Changes of the slice area during the heart cycle for each hypertensive MI patient. The prolonged relaxation can be observed in nearly all patients. The area was normalized by the maximum.

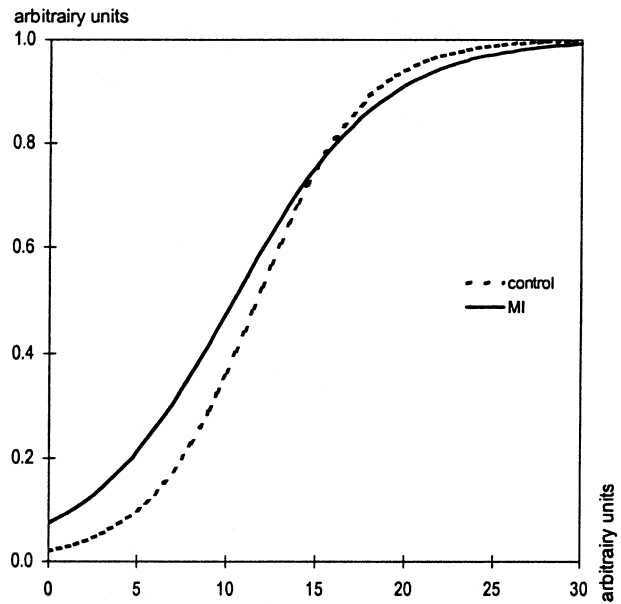


Figure 6. Fermi functions obtained from the median slope and shift for both groups:

$$\frac{1}{1 + e^{(-ax + SHIFT)}} \quad (a \text{ depicts the slope}).$$

4. Discussion

This report introduces new markers for the diastolic function. To test the feasibility of the new markers patients with regional systolic dysfunction (that mostly also coincident with diastolic dysfunction) and hypertension as well as left ventricular hypertrophy were tested and compared against a normal control group. Although patients suffered from both systolic and diastolic dysfunction we focused on the diastolic function only.

Diastolic dysfunction includes delayed relaxation, increased stiffness and/or impaired filling.

The slope of the function that depicts the diastolic increase of the short axis slice area reflects relaxation speed. This parameter was already investigated and was also addressed in a MRI study [3]. In this study it was automatically determined by a linear least-squares fit and significantly lower in the hypertensive MI patients as compared to the MI group.

A new feature, the shift parameter of the least-squares fit of the sigmoid Fermi-function can be visually observed in Fig. 2 and reflects a delay of the relaxation.

The third feature also differed significantly in both groups. The irregularity index may reflect the systolic wall motion abnormality in the MI patients as well as an uncoordinated relaxation. Dendale et al [4] observed an increased asynchronicity of contraction as well as relaxation in patients after myocardial infarction. This needs further investigation in a collective with a distinct diastolic dysfunction such as patients without coronary artery disease but an elevated left ventricular enddiastolic pressure. In this setting the first two features should be influenced as well, but the irregularity index may not be affected so that it may serve to discriminate systolic from diastolic dysfunction objectively.

In Fig. 3, there are some control individuals, who seem to show a later relaxation. To address this observation we divided the control group in two subgroups and employed the three features. No significant difference was found. However, a larger collective is needed to confirm the finding.

Furthermore, in some individuals the initial area at the beginning of the heart cycle is not fully attained in the last frame. This can be explained by the heart synchronization used in the this study. Prior to scanning, an estimated heart frequency and a gating window (5% in

this study) has to be entered. That means the last five percent of the heart cycle are used for r-wave detection and cannot be utilized for data acquisition. If the actual heart rate is slower than the entered heart rate, the full heart cycle will not be used for scanning. Since there are only minor changes of the area in the last frames this should not alter the general diastolic area change. The problem may be overcome by using other synchronization methods like retrospective gating.

5. Conclusion

We conclude that these features may serve as promising objective and quantitative parameters for the assessment of the diastolic left ventricular function. Further studies with different subcollectives and comparisons with conventional methods such as Doppler echocardiography are necessary to fully evaluate the found markers.

References

- [1] Little WC, Downes TR. Clinical evaluation of left ventricular diastolic performance. *Prog Cardiovasc Dis* 1990; 32:273-290
- [2] Hartiala JJ, Mostbeck GH, Foster E, Fujita N, Dulce MC, Chazouilleres AF, Higgins CB. Velocity-encoded cine MRI in the evaluation of left ventricular diastolic function: measurement of mitral valve and pulmonary vein flow velocities and flow volume across the mitral valve. *Am Heart J* 1993; 125:1054-1066
- [3] Hoff FL, Turner DA, Wang JZ, Barron JT, Chutuape MD, Liebson PR. Semiautomatic evaluation of left ventricular diastolic function with cine magnetic resonance imaging. *Acad Radiol* 1994; 1:237-242.
- [4] Dendale PA, Franken PR, Waldman GJ, Baur LH, Vandamme S, van der Geest RJ et al. Regional diastolic wall motion dynamics in anterior myocardial infarction: analysis and quantification with magnetic resonance imaging. *Coron Artery Dis* 1995; 6(9):723-729.

Address for correspondence:

Olaf Grebe, M.D.
University of Ulm
Dept. of Cardiology
Robert-Koch-Str. 8
89081 Ulm, Germany
Email: olaf.grebe@medizin.uni-ulm.de