

Semi-automatic Detection and Tracking of Mitral and Aortic Annuli from Real-Time 3D Transesophageal Echocardiographic Images

F Veronesi^{1,2}, C Corsi¹, V Mor-Avi², L Sugeng², EG Caiani³, L Weinert², C Lamberti¹, RM Lang²

¹University of Bologna, Bologna, Italy

²University of Chicago, Chicago, Illinois, USA
Politecnico di Milano, Milan, Italy

Abstract

The recently developed echocardiographic matrix array transesophageal (mTEE) transducer provides real-time 3D images of high spatial and temporal resolution that may be suitable for detailed simultaneous study of functional anatomy of the mitral and aortic valves. We developed software that detects and tracks throughout the cardiac cycle mitral and aortic annuli (MA and AoA) and tested it in 15 patients with normal valves. Following manual initialization of each annulus in 15 planes rotated around the valve's axis, the position of each annulus was tracked using a two-step 3D feature tracking algorithm based on maximum likelihood and Lucas-Kanade optical flow techniques and parameters of valve geometry were automatically measured throughout the cardiac cycle. Frame-by-frame detection and tracking of MA and AoA was possible in all patients. This approach allowed for the first time non-invasive quantitative measurements of the 3D dynamic geometry of normal MA and AoA and their coupling from mTEE data.

1. Introduction

The mitral and aortic valves are coupled via fibrous tissue connecting the two annuli. The understanding of normal mitral-aortic valvular coupling and the ability to accurately assess changes in different disease states is important in for valvular surgical planning and post-surgical assessment. However, this coupling is difficult to evaluate using 2D imaging techniques because of the 3D anatomy of these structures. Consequently, the aortic and mitral valves have been studied in humans separately as if their function was independent of each other. Assessment of the mitral valve dynamics in humans using 3D echocardiographic techniques, such as gated acquisition of multiple slices for volume reconstruction, and the more recent transthoracic real-time 3D echocardiography (RT3DE), is limited by either low temporal resolution, which allows only measurements at one phase of the

cardiac cycle, or by low spatial resolution, which limits the visualization of valve morphology during dynamic assessment [1-3]. Because the motion of the aortic valve complex is even more difficult to characterize, few studies have studied the functional anatomy of this valve in 3D. These studies have been mostly limited to invasive techniques in animals [4,5]. There is growing evidence that the dynamics of these two annuli throughout the cardiac cycle are inter-related, and that their coupling is an integral part of the normal cardiac physiology.

To allow the non-invasive evaluation of this coupling, it is essential to have a 3D technique that allows simultaneous imaging of both valves at high spatial and temporal resolutions. The recently developed RT3DE matrix array transesophageal (mTEE) transducer provides superb image quality with unparalleled level of spatial and temporal detail. Our hypothesis was that these images could be suitable for: (1) detailed study of functional anatomy of the aortic valve, and (2) simultaneous analysis of mitral and aortic valves that would allow quantitative assessment of their dynamic behavior and accurate characterization of their coupling. To test this hypothesis, we developed and tested software for quantification of mitral and aortic valve dynamics from mTEE images.

2. Methods

Twenty-four patients (7 males; age 54±20 years) were studied during a clinically indicated transesophageal echocardiography, which was performed according to standard protocol. Inclusion criteria were: 1) normal aortic valve and absence of aortic root abnormalities and aortic regurgitation; 2) normal mitral valve with no more than trace mitral regurgitation; 3) normal left ventricular (LV) volumes and function.

2.1. Real-time 3D echocardiography

The TEE study was performed using the iE33 ultrasound system (Philips) equipped with the mTEE transducer (x7). The scan volume in the wide-angled acquisition

mode included the mitral apparatus, the aortic valve and proximal ascending aorta, while excluding the mid and apical ventricular segments to maximize frame rate (figure 1). This full-volume mode uses ECG gating to merge 6 narrow pyramidal scans obtained over 6 consecutive heartbeats. To avoid stitch artifacts, special care was taken to minimize patient’s movements and to stabilize the probe during data acquisition.

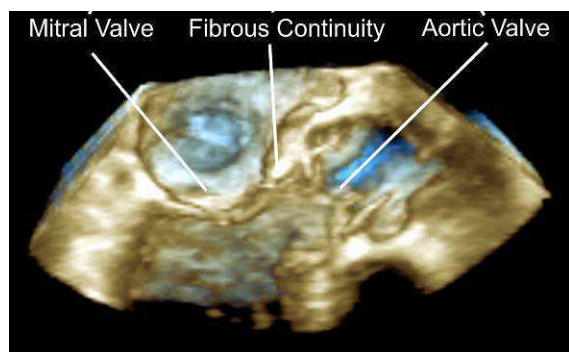


Figure 1. Volume rendering of RT3DE matrix TEE data visualized in a long axis view.

2.2. RT3DE data analysis

The RT3DE datasets were analyzed using custom software designed to quantify the dynamic behavior of the MA and AoA. Briefly, this was achieved by semi-automatically detecting these structures and then automatically tracking them in 3D throughout the cardiac cycle using optical flow and region-based matching techniques, which are based on the analysis of speckle noise patterns within the 3D datasets [6]. Then, the tracked points were displayed frame-by-frame throughout the cardiac cycle to visually verify their position in 3D space, and manual corrections of these points were performed when necessary. Several parameters were automatically measured on the detected annuli throughout the cardiac cycle.

2.3. Mitral annulus measurements

Initially, a cut plane representing the 3-chamber view at end-diastole (ED) was selected, and two points were identified on the anterior (MA saddle-horn, MA1) and posterior (MA2) mitral valve annulus. This initialization was then repeated (MA3 and MA4) on an orthogonal plane crossing the center of the line connecting MA1 and MA2. The middle point of the segment connecting MA3 and MA4 was considered as the MA center. Subsequently, 15 long-axis cut planes evenly rotated around the MA center (12° steps) were displayed and on each plane, the operator selected two points, one on each side of the MA. The same procedure was then applied to

the isovolumic relaxation (End-IVR) frame. After automatic tracking, MA points were connected using spline interpolation to obtain the annular line (figure 2). Finally, a 3D MA surface was generated for each consecutive frame throughout the cardiac cycle by connecting the points with a triangulated mesh. The highest point of MA was used to define the center of mitral valve saddle. The MA was split into two parts: 1) the anterior fibrous part computed as 120° -wide MA portion centered on the previously computed saddle point, and 2) the posterior part corresponding to the remaining 240° portion of MA. The sequence of 3D MA surfaces and annular lines was used to obtain the following measurements throughout the cardiac cycle to describe the dynamic behavior of the MA: (1) MA surface area calculated as the sum of areas of all mesh triangles; (2) MA surface area change normalized by the MA surface area at ED; (3) longitudinal displacement of the whole MA and separately its anterior and posterior portions computed as the average motion of all MA points along the direction orthogonal to the MA surface; (4) mitral valve height, computed as the distance between the highest and the lowest MA points in the direction orthogonal to the mitral valve.

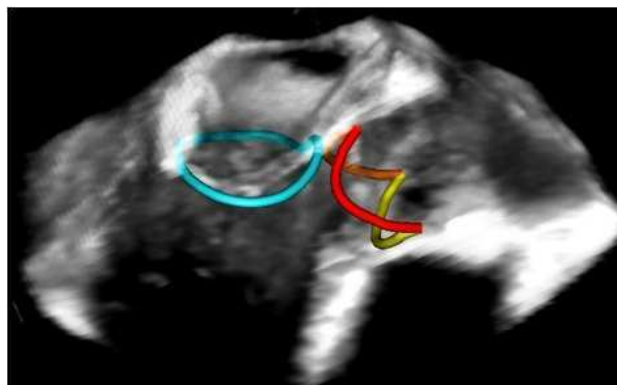


Figure 2. Computed mitral annulus (cyan) and aortic annulus (red = non-coronary cusp, orange = right cusp, yellow = left cusp). Splines are shown superimposed on RT3DE volume rendering.

2.4. Aortic annulus measurements

In this study, the term “aortic annulus” refers to the line representing the insertion of the aortic cusps into the sinuses of Valsalva (figure 2). First, two points on the AoA were manually initialized at ED phase on a cut plane of the volume dataset. Then, the orthogonal plane crossing the center of the line connecting these two points was displayed, and two additional points were selected on the AoA. From these four points, the vector orthogonal to the AoA was automatically computed and used as the vertical axis of the AoA. Fifteen vertical cut planes

passing through this axis (12° apart) were displayed one-by-one and two AoA points were identified on each plane. Using these additional points, the vertical axis of the AoA was recalculated. This allowed viewing of a series of cut planes parallel to the AoA, that represent the short axis views of the outflow tract, base of the aortic cusps, cusp coaptation point, inter-atrial septum, sinus of Valsalva and sino-tubular junction. The positions of the coaptation point and the inter-atrial septum were manually marked on the ED frame. The same procedure was then applied to end-systolic (ES) frame.

These AoA points were automatically tracked throughout the cardiac cycle and connected using three splines, one for each cusp in every frame (figure 2). The inter-atrial point was used as reference position to identify the non-coronary aortic cusp, and then to identify the left and right cusps. Multiple parameters of AoA geometry shown in figure 3 were calculated at ED phase.

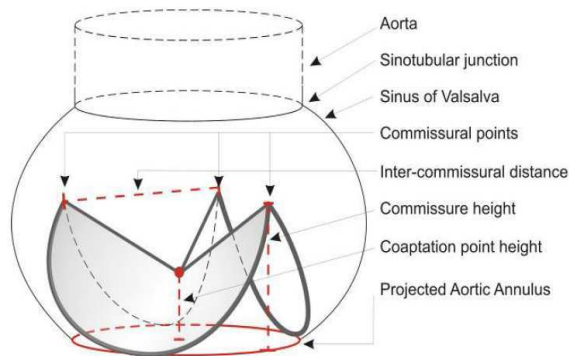


Figure 3. Schematic of aortic annulus measurements.

2.5. Statistical analysis

Parameters were averaged for all patients at ED and when possible at isovolumic contraction (IVC), ES and End-IVR. Differences between parameters computed at these four phases were tested using non-parametric paired Friedman test with Bonferroni corrections for repeated measures. Comparisons between the groups for non-coronary, left and right cusps were tested using three-factor non-parametric paired Friedman test with Bonferroni correction.

3. Results

Images obtained with the mTEE transducer were of high quality and allowed MA and AoA tracking throughout the cardiac cycle, and detailed measurements of valve geometry parameters in all patients. Maximum and minimum values were 9.9 ± 2.2 cm² and 7.7 ± 2.1 cm² for MA area, and 4.8 ± 1.3 cm² and 3.6 ± 1.0 cm² for AoA projected area, respectively. When MA area was maximal

during early diastole, AoA projected area was at its minimum, and vice versa during systole. Thus, the two parameters that describe valve area exhibited a synchronized reciprocal behavior. The minimum value for the angle between mitral and aortic valves occurred at ES and was significantly smaller than the angle measured at ED, IVC and End-IVR.

We found that AoA center remained throughout the cardiac cycle in the same plane, corresponding to the 3-chamber view. This plane also contained the MA center. During the period of IVC, as the LV pressure increased, the AoA moved outwards increasing AoA-MA center distance from 25.0 ± 3.2 to 25.8 ± 3.1 mm ($p < 0.0001$). Subsequently, during systole, as the ventricle ejected, both the AoA and MA moved in synchrony toward the apex. Then, during the IVR, as the pressure in the ventricle declined, the AoA moved inward, reaching minimal distance between the centers of the two annuli (25.0 ± 3.5 mm). Finally, during diastole the AoA moved towards the LV base, thus completing a loop and reaching its original position. MA-AoA angle was maximal ($137 \pm 14^\circ$) at ED and decreased to its minimum value ($123 \pm 11^\circ$) in systole.

The measured parameters reflected the changes in MA geometry throughout the cardiac cycle. MA surface area reached its maximum value during early diastole ($63.9 \pm 9.0\%$ of RR) shortly after mitral valve opening, while the MA surface area minimum value occurred during ventricular systole ($23.0 \pm 20.3\%$ of RR). MA area change from MA area at ED ranged from a minimum value of $-4.4 \pm 6.1\%$ to a maximum value of $25.4 \pm 12.7\%$. As expected, the MA motion curve resembled the LV volume curve [2] and reached its maximum distance from MA ED position at ES (7.7 ± 2.8 mm). Mitral valve height, which represents MA non-planarity, was equal to 7.4 ± 1.6 mm at end-diastole, then increased during systole to 8.1 ± 1.7 mm and then decreased gradually during diastole.

Similarly, parameters describing the changes in AoA geometry throughout the cardiac cycle were quantified. At end-diastole, aortic cusp areas were 1.6 ± 0.7 , 1.8 ± 0.8 and 1.7 ± 0.7 cm² for the non-coronary, left and right cusps, respectively. At ED, the height of the coaptation point above the aortic basal plane was 6.9 ± 1.8 mm, while aortic inter-commissural distances were 19.4 ± 3.1 , 20.1 ± 3.2 and 19.1 ± 3.2 mm respectively for non-coronary, left and right cusps.

The AoA projected area was equal to 4.1 ± 1.2 cm² at end-diastole, then during isovolumic contraction it rapidly increased reaching its peak (4.8 ± 1.3 cm²) during the first third of systole ($19 \pm 12\%$ RR), and then gradually decreased to 3.8 ± 1.1 cm² at ES, with its minimum value (3.6 ± 1.0 cm²) measured at $57 \pm 17\%$ of RR phase. The same pattern was noted in the total annular length and the inter-commissural distances.

4. Discussion and conclusions

This is the first study to develop and test a non-invasive technique for detailed characterization of aortic valve dynamics and quantitative evaluation of mitral and aortic valvular coupling throughout the cardiac cycle in a beating human heart using the newly developed mTEE 3D imaging technology.

The observations made for the two valves suggest that the fibrous continuity acts as an anchor simultaneously affecting the dynamics of both valves, i.e. plays an important role in mitral-aortic coupling, refuting the notion of their independent behavior. Consequently, the projected AoA and MA surface areas throughout the cardiac cycle demonstrated coupled reciprocal behavior, which to our knowledge has not been quantified in humans. Specifically, the timing of the maximum and minimum values of MA and AoA projected areas was inverted: when the MA area reached its maximum value in early diastole, the AoA projected area was minimal, and vice versa, during systole while the aortic valve was open, the MA area was minimal and the AoA projected area was maximal. This reciprocity may contribute toward improved efficiency of the heart as a pump, because AoA contraction may facilitate MA expansion and vice versa. Another factor characterizing the mitral-aortic coupling is the angle between the two valves. Our results showed that this angle decreased during ejection, possibly also facilitating ejection of blood through the aortic root. This finding further supports the notion of the role of the fibrous continuity as an anchor that maintains its position while the two annuli move towards each other. These findings underscore the need to consider the aortic and mitral valves jointly, rather than as separate entities, not only because they are linked anatomically, but also because their dynamic changes in shape and position are reciprocally correlated.

With the improved understanding of mitral valve functional anatomy, mitral valve repair, as opposed to replacement, is increasingly becoming the surgical approach of choice. Continuous development of new prosthetic mitral annuli with a variety of shapes, specifically designed to preserve the shape function of the MA based on the knowledge gained through 3D studies, is likely to result in significant improvements in the outcomes of mitral valve repair. It is also likely that quantitative analysis of RT3DE mTEE images, such as described in this study, will enhance the understanding of AoA physiology and thus contribute toward the development of better techniques for aortic valve repair. In addition, our results demonstrated the potential of the new RT3DE mTEE technology to quantitatively assess important parameters describing aortic and mitral valve coupling.

In summary, to our knowledge, this is the first study to simultaneously quantify the functional anatomy of the mitral and aortic valves in three dimensions in a beating human heart and to investigate their coupled behavior using the new RT3DE mTEE imaging technology. We were able to measure potentially clinically useful parameters and characterize the unique 3D geometry of the normal aortic and mitral annuli. The methodology described in this paper may become an important tool for pre-surgical planning and serial follow-up of patients with valvular disease.

References

- [1] Kwan J, Shiota T, Agler DA, Popovic ZB, Qin JX, Gillinov MA, Stewart WJ, Cosgrove DM, McCarthy PM, Thomas JD. Geometric differences of the mitral apparatus between ischemic and dilated cardiomyopathy with significant mitral regurgitation: real-time three-dimensional echocardiography study. *Circulation* 2003; 107: 1135-40
- [2] Veronesi F, Corsi C, Sugeng L, Caiani EG, Weinert L, Mor-Avi V, Cerutti S, Lamberti C, Lang RM. Quantification of Mitral Apparatus Dynamics in Functional and Ischemic Mitral Regurgitation Using Real-time 3-Dimensional Echocardiography. *J.Am.Soc.Echocardiogr.* 2008; 21: 347-54
- [3] Watanabe N, Ogasawara Y, Yamaura Y, Wada N, Kawamoto T, Toyota E, Akasaka T, Yoshida K. Mitral annulus flattens in ischemic mitral regurgitation: geometric differences between inferior and anterior myocardial infarction: a real-time 3-dimensional echocardiographic study. *Circulation* 2005; 112: I458-I462
- [4] Lansac E, Lim HS, Shomura Y, Lim KH, Rice NT, Goetz W, Acar C, Duran CM. A four-dimensional study of the aortic root dynamics. *Eur.J.Cardiothorac.Surg.* 2002; 22: 497-503
- [5] Dagum P, Green GR, Nistal FJ, Daughters GT, Timek TA, Foppiano LE, Bolger AF, Ingels NB, Jr., Miller DC. Deformational dynamics of the aortic root: modes and physiologic determinants. *Circulation* 1999; 100: II54-II62
- [6] Veronesi F, Corsi C, Caiani EG, Sarti A, Lamberti C. Tracking of left ventricular long axis from real-time three-dimensional echocardiography using optical flow techniques. *IEEE Trans.Inf.Technol.Biomed.* 2006; 10: 174-81

Address for correspondence:

Federico Veronesi, PhD
University of Bologna,
viale Risorgimento 2, 40125 Bologna, Italy
E-mail: federico.veronesi@unibo.it