

# Diagnostic Value of Parametric Imaging of Left Ventricular Wall Motion from Contrast-Enhanced Echocardiograms in Patients with Poor Acoustic Windows

N Kachenoura<sup>1,2</sup>, V Mor-Avi<sup>1</sup>, F Frouin<sup>2</sup>, A Delouche<sup>2</sup>, TS Tamar<sup>1</sup>, S D'Amore<sup>1</sup>,  
B Diebold<sup>2</sup>, RM Lang<sup>1</sup>

<sup>1</sup>University of Chicago, Chicago, Illinois, USA  
<sup>2</sup>Inserm U678, UMPC Univ Paris 6, Paris, France

## Abstract

*Echocardiographic analysis of regional left ventricular wall motion (RWM) is challenging in patients with suboptimal images even with contrast. We hypothesized that parametric images obtained from contrast-enhanced (CE) images can accurately describe RWM and thus improve the diagnostic accuracy of inexperienced readers. CE images were acquired in 45 patients with poor acoustic windows. Expert interpretation of RWM was used as a reference for comparisons against: (1) visual reading of parametric images, (2) interpretation of dynamic images by two inexperienced readers with and without parametric images, (3) quantitative analysis of RWM. Visual reading of parametric images showed good agreement with the expert (84%). Inexperienced readers increased their accuracy from 74 to 84%. Automated classification was feasible and accurate (80%). Parametric images derived from CE images of patients with poor acoustic windows accurately depicted RWM, improved the diagnostic accuracy of inexperienced readers, and allowed objective detection of RWM abnormalities.*

## 1. Introduction

Evaluation of left ventricular RWM in clinical practice is mostly based on visual interpretation of dynamic two-dimensional images. This analysis relies on the reader's ability to integrate for each myocardial segment multiple parameters, including magnitude and timing of endocardial motion and wall thickening, while simultaneously compensating for cardiac translation and rotation. This complex process results in a subjective decision, which is strongly influenced by training and experience and is thus subject to wide variability [1]. Besides, echocardiographic assessment of RWM can be even more challenging in patients with poor acoustic windows, in whom contrast agents are frequently used to enhance endocardial visualization and thus improve

diagnosis accuracy [1]. However, in these patients, both accuracy and reproducibility of interpretation remain far from optimal even with contrast enhancement [1].

We have previously developed a technique for parametric imaging of endocardial motion [2, 3], which generates from dynamic images of the heart obtained over a single cardiac cycle parametric images that provide a simplified display of spatial and temporal information on RWM. This methodology was previously tested on non-enhanced echocardiographic images [2] as well as cardiac magnetic resonance images [3], proving its usefulness for the interpretation of RWM. However, the usefulness of parametric images generated from CE echocardiograms obtained in patients with poor acoustic windows has not been tested. Since contrast enhancement improves endocardial visualization, it is likely to also improve the quality of parametric images and thus provide diagnostic information in patients whose images are difficult to interpret. Accordingly, the aims of this study were: (1) to test whether CE parametric images accurately represent the amplitude and timing of RWM by comparing them against expert visual interpretation of dynamic CE echocardiograms, (2) to determine whether the addition of these parametric images to dynamic images can improve the diagnostic accuracy of the interpretation of RWM by inexperienced readers, (3) to test the feasibility of automated quantitative analysis of RWM.

## 2. Methods

Sixty patients (36 males, 24 females, mean age 64±12 years) were studied using the iE33 imaging system with an S5-1 transducer (Philips). Patients were selected on the basis of suboptimal image quality, as defined by lack of endocardial visualization without contrast enhancement in at least two contiguous segments in each apical view (2-, 3- and 4-chamber). Contrast enhancement was achieved using Definity contrast agent (Bristol-Myers Squibb; 1.3 ml in 50 ml saline, i.v. drip). For each apical view, one cardiac cycle that was visually judged to be least affected by cardiac translation, was selected for analysis.

## 2.1. Study design

The study included three separate protocols, which were designed to address each of the goals 1, 2 and 3 above. Dynamic CE echocardiograms were reviewed by an expert echocardiographer who classified wall motion in each myocardial segment as either normal or abnormal. This expert interpretation of RWM was used as a reference for comparisons in all three protocols. The 60 patients were divided into two groups with similar prevalence of wall motion abnormalities: the study group of 45 patients that was used in all three protocols and a second independent group of 15 patients, which was used in protocol 3, as described below.

Protocol 1 was designed to validate the visual assessment of RWM from the parametric images. To achieve this goal, the parametric images were reviewed by an independent investigator familiar with the technique and blinded to the reference interpretation, who classified RWM in each segment.

Protocol 2 was designed to test the hypothesis that the addition of parametric images to dynamic images could improve the diagnostic accuracy of interpretation by inexperienced readers. Accordingly, two inexperienced readers (ASE level I) reviewed the dynamic CE echocardiograms and independently classified RWM in each segment. Two weeks later, the same two readers participated in an additional reading session. After being informed of the nature of the parametric images and the information displayed there, they reviewed the dynamic echocardiograms in combination with the corresponding parametric images.

Protocol 3 was designed to test the feasibility of automated, objective interpretation of RWM by quantitative analysis of the parametric images. First, parametric images obtained in both patient groups (total of 60 patients) were analyzed to quantify RWM in terms of thickness of regional color band and contraction timing. Then, data obtained in the subgroup of 15 patients was used to estimate an abnormality threshold using Receiver Operating Characteristic (ROC) analysis. This threshold was used to test the feasibility of automated detection of RWM abnormalities in the study group of 45 patients.

In all three protocols, images were reviewed using a standardized LV segmentation (figure 1B) to avoid inter-individual segmentation differences.

## 2.2. Construction of parametric images

Figure 1 demonstrates how parametric images were created by showing examples of a patient with normal RWM. Videointensity in a fixed pixel (figure 1A) located at end-diastole inside the LV cavity near the endocardial border abruptly decreases during systole, as soon as this

pixel transitions from bright LV cavity into darker myocardium. Conversely, the videointensity increases during diastole, when the pixel transitions back into LV cavity (figure 1A, right). This curve has a reversed shape in segments that paradoxically move out in systole.

Modeling videointensity curves of each pixel throughout the cardiac cycle using a window function allows extraction of 3 parameters (figure 1A):  $V$  – the magnitude of variation in gray levels, which can be either positive or negative depending on the direction of the endocardial motion; and the two transition times  $T_{ON}$  and  $T_{OFF}$ , from which mean transition time  $\tau$  was calculated by averaging the two values and then normalized by the RR interval ( $\tau_n$ ) to allow comparisons between patients. To distinguish between inward and outward endocardial motion, the mean transition time was given the sign of the parameter  $V$ . Two parametric images were created: one of  $V$  (figure 1C) and the other of  $\tau_n$  (figure 1B). In both images, we used color scales in which red and blue tones represented inward and outward motion, correspondingly. In addition, clutter in the LV cavity in the parametric image of  $\tau_n$  was eliminated by detecting in the image of  $V$  low amplitude variations in pixels that remained inside the LV cavity throughout the cardiac cycle.

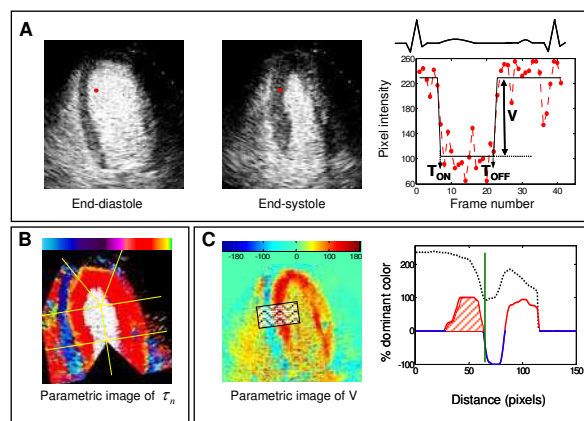


Figure 1. Principle of parametric imaging of left ventricular (LV) wall motion and principle of quantification of regional wall motion in a patient with normal (LV) function. See text for details.

The resultant mean transition time images (figure 1B) were used for the visual interpretation of RWM, since these images combined information on both amplitude and timing of wall motion. Accordingly, normal wall motion was assigned to segments, in which a wide red band surrounded the LV cavity. In contrast, abnormal wall motion was assigned to segments, in which a thin red and/or yellow-green band, indicating reduced or delayed wall motion, respectively, surrounded the LV cavity. Also, paradoxical motion reflected by blue color around the LV cavity was classified as abnormal.

### 2.3. Quantification of LV wall motion

Images of parameter  $V$  were used to quantify the amplitude of wall motion in each segment. To this effect, segmental profiles were created to show the number of pixels of the predominant color tones as a function of distance from the LV long axis (figure 1C, right). To allow comparisons between segments and patients, this parameter was expressed as percent of the total number of colored pixels found at that particular distance. These profiles varied between -100 and 100, with these two extreme values representing distances at which all pixels were moving outwards and inwards, respectively. To estimate the amplitude of endocardial motion, the area under the profile was calculated up to either the end-diastolic endocardial position or the distance where the first change in the sign of the profile occurs (as a way to avoid discarding dyskinetic segments), whichever of the two occurs last. Finally, to create a single combined index of amplitude and timing of RWM, the segmental area under profile (shaded area) was divided by mean transition time in order to use the information on delayed contraction. This combined index was used for automated detection of RWM abnormalities in the study group, after its threshold value was optimized by the ROC analysis.

## 3. Results

The expert reader determined that 15/45 patients enrolled in the study group had normal wall motion, and detected abnormalities in 437/945 (46 %) segments in the remaining 30/45 patients. Of these 30 patients, 15 had dilated cardiomyopathy (DCM) and the other 15 patients had RWM abnormalities. In the group of 15 patients used for ROC analysis, RWM abnormalities were noted in 131/315 (42 %) segments in 12 patients.

### 3.1. Protocol 1

The quality of parametric images was judged as diagnostically adequate in the majority of patients. Figure 2 shows examples of parametric images of  $\tau_n$  obtained in a patient with normal LV function (top), a patient with RWM abnormalities (middle) and a patient with DCM (bottom). Normal wall motion is characterized by a wide red band which surrounds the LV cavity (figure 3 top) while abnormal wall motion is reflected by thinned color bands surrounding the LV cavity locally in the patient with RWM abnormalities (figure 2 middle) and in all the LV walls in the patient with DCM (figure 2 bottom). All abnormalities were confirmed by the reference technique.

Comparisons of the segmental grades obtained from the visual analysis of the parametric images in the entire study group with the reference grades resulted in high levels of agreement as reflected by sensitivity, specificity, PPV, NPV and accuracy above 80% (Table 1).

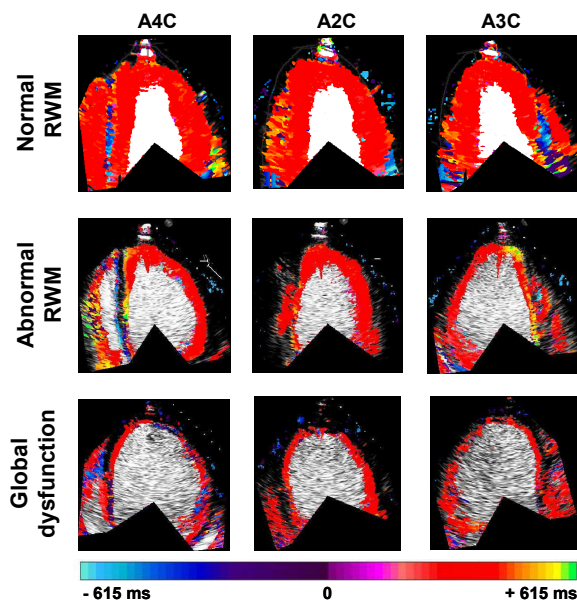


Figure 2. Examples of mean transition time images obtained in the apical 4-chamber view (A4C), 2-chamber view (A2C), and 3-chamber view (A3C) in a patient with normal wall motion (top), a patient with RWM abnormalities (middle), and a patient with global LV dysfunction due to dilated cardiomyopathy.

### 3.2. Protocol 2

For both inexperienced readers, the interpretation of the dynamic contrast-enhanced images alone resulted in high sensitivity and NPV, but relatively low specificity and PPV. Importantly, the addition of the parametric images of mean transition time improved the accuracy of RWM interpretation by both inexperienced readers. Statistics of agreement with the reference grades are summarized in Table 1, separately for the interpretation with and without the parametric images, both averaged for the two readers.

### 3.3. Protocol 3

Combined index of amplitude and timing of RWM extracted from the parametric images of the 15 patients (315 segments) was used for the ROC analysis to optimize the abnormality threshold. In this group, with the optimal threshold, the agreement between the automated classification and the reference technique was: sensitivity 85%, specificity 82% and accuracy 83%. When applied to the study group 45 patients (945 segments), the automated classification resulted in similar levels of agreement against the reference technique (Table 1).

		Sensitivity (%)	Specificity (%)	PPV (%)	NPV (%)	Accuracy (%)
Visual interpretation of parametric images		85	82	81	87	84
Inexperienced readers	Dynamic only	92	58	65	89	74
	Dynamic + parametric	91	79	79	92	84
Quantitative analysis of parametric images		83	78	76	84	80

Table 1. Agreement between different interpretations of regional wall motion and the reference technique based on expert visual interpretation of dynamic contrast-enhanced echocardiograms in the study group of 45 patients (945 myocardial segments).

#### 4. Discussion and conclusions

Echocardiography is the most frequently used imaging modality for the evaluation of LV RWM in ischemic heart disease. Traditionally, wall motion abnormalities are diagnosed by visual interpretation, which is subjective and strongly depends on both image quality and the experience of the reader. It has been suggested that quantitative parameters that describe RWM can be used to generate parametric images of LV wall motion, which may be easier to interpret. Importantly, the use of such still frames in combination with dynamic images may improve the confidence of the reader, particularly the inexperienced one, and thus reduce the variability in the interpretation of RWM. Accordingly, several techniques such as color kinesis [4], the Fourier transform [5] and the factor analysis [6] based methods have been proposed. However, these techniques either did not take into account the timing of endocardial motion or depended on gain settings, which are necessary for accurate endocardial border detection and tracking.

In this study, a quick parametric imaging technique, which automatically generates still-frame images combining information on both amplitude and timing of endocardial motion, was used in patients with poor acoustic windows who had CE echocardiograms. As a result of the improved quality of CE echocardiograms, the quality of the still-frame parametric images was good and the classification of RWM based on their visual analysis was in good agreement with the expert visual interpretation of dynamic echocardiograms, and, importantly, more accurate than the inexperienced readers' interpretation of RWM from dynamic images alone (Table 1). Similarly, the objective classification of RWM from these parametric images showed relatively high levels of agreement with the reference technique (Table 1). Another important result of this study is that inexperienced readers considerably increased the accuracy of the detection of RWM abnormalities with the aid of the parametric images.

Similar to all techniques that track the endocardium, our method is affected by cardiac translation. In this study this limitation was minimized by manual selection of cardiac cycles most suitable for analysis.

In summary, our results demonstrated the usefulness of

parametric images of mean transition time derived from CE echocardiograms in characterizing RWM. These images were found to be sensitive enough to allow accurate diagnosis of RWM abnormalities in patients with poor acoustic windows. Importantly, when combined with dynamic loops, these images improved the accuracy of the interpretation by less experienced readers, supporting the clinical use of our technique.

#### References

- [1] Hoffmann R, von BS, Kasprzak JD, Borges AC, ten CF, Firschke C, Lafitte S, Al-Saadi N, Horstick G, Greis C, Engelhardt M, Vanoverschelde JL, Becher H: Analysis of regional LV function by cineventriculography, cardiac magnetic resonance imaging, and unenhanced and contrast-enhanced echocardiography: a multicenter comparison of methods. *J Am Coll Cardiol* 2006; 47: 121-8
- [2] Kachenoura N, Redheuil A, Balvay D, Ruiz-Dominguez C, Herment A, Mousseaux E, Frouin F: Evaluation of regional myocardial function using automated wall motion analysis of cine MR images: Contribution of parametric images, contraction times, and radial velocities. *J Magn Reson Imaging* 2007; 26: 1127-32
- [3] Ruiz DC, Kachenoura N, De CA, Delouche A, Lim P, Gerard O, Herment A, Diebold B, Frouin F: Assessment of LV contraction by parametric analysis of main motion: theory and application for echocardiography. *Phys Med Biol* 2005; 50: 3277-96
- [4] Lang RM, Vignon P, Weinert L, Bednarz J, Korcarz C, Sandelski J, Koch R, Prater D, Mor-Avi V: Echocardiographic quantification of regional LV wall motion with color kinesis. *Circulation* 1996; 93: 1877-85
- [5] Caiani EG, Lang RM, Korcarz CE, DeCara JM, Weinert L, Collins KA, Spencer KT, Mor-Avi V: Improvement in echocardiographic evaluation of LV wall motion using still-frame parametric imaging. *J Am Soc Echocardiogr* 2002; 15: 926-34
- [6] Frouin F, Delouche A, Raffoul H, Diebold H, Abergel E, Diebold B: Factor analysis of the left ventricle by echocardiography: a new tool for detecting regional wall motion abnormalities. *Eur J Echocardiogr* 2004; 5: 335-46

Address for correspondence:

Nadjia Kachenoura, PhD  
 University of Chicago MC5084,  
 5841 S. Maryland Ave., Chicago Illinois 60637.  
 E-mail: [nadjia.kachenoura@gmail.com](mailto:nadjia.kachenoura@gmail.com)