

Quantitative Assessment of Changes in Left Ventricular Shape following Mitral Valve Repair

F Maffessanti^{1,2}, G Tamborini², M Muratori², M Zanobini², V Mor-Avi³, L Sugeng³,
F Alamanni², RM Lang³, M Pepi², EG Caiani¹

¹Bioengineering Department, Politecnico di Milano, Milano, Italy

²Department of Cardiovascular Sciences, Centro Cardiologico Monzino IRCCS, Milano, Italy

³Cardiac Imaging Center, University of Chicago Medical Center, Chicago, IL, USA

Abstract

Mitral valve (MV) repair is the preferential treatment for mitral regurgitation (MR) associated with degenerative MV disease, and the functional benefits of early surgery are known. Our goal was to evaluate the changes in LV shape following MV repair, using a new method based on real-time 3D echocardiography (RT3DE). Fifty patients with severe asymptomatic MR were enrolled. Transthoracic RT3DE imaging was performed the day before, 6 and 12 months after MV repair. A group of 66 normal subjects (NL) was studied as a reference. LV 3D shape indices of sphericity (S) and conicity (C) were computed. Post-operatively, LV volumes were decreased compared to pre-surgical values. EF was slightly decreased 6 months after surgery, but restored at 12 months. Modifications in end-diastolic LV shape were found: prior to surgery, S was elevated and C was decreased compared to NL; at 6 months, these changes were reversed with no further improvement at 12 months. Early MV repair in asymptomatic patients is associated with changes in LV shape which remodels to near normal morphology. Novel 3D shape analysis based on RT3DE, allows serial examination of the complex relationship between LV performance and shape.

1. Introduction

Mitral valve (MV) repair is the preferred technique for the treatment of mitral regurgitation (MR) associated with either a degenerative prolapse or flail valve, since it allows preserving both the MV apparatus and left ventricular (LV) geometry and function [1]. Pre-operative presence of severe symptoms is associated with an unfavorable post-operative outcome [2]. In the recent guidelines, early surgery is recommended even in asymptomatic patients when the likelihood of repair is high [3].

The complex pre- and post-operative relationship between LV function and shape has been studied mainly

with 2D echocardiography-based shape indices, which are intrinsically limited by the geometric assumptions needed to describe the 3D LV shape from 2D images. Recently, we proposed a new technique for the computation of 3D shape indices from LV endocardial surfaces extracted from real-time three-dimensional echocardiography (RT3DE) datasets [4].

We hypothesized that this methodology could be applied to serially follow the subtle changes in LV morphology associated with MV repair. Accordingly, the aims of this study were: 1) to obtain reference values for 3D shape indices in a group of normal subjects; 2) to assess changes in LV shape after an early MV repair for severe MR in asymptomatic patients.

2. Methods

2.1. Patient population

We studied 116 subjects, divided into two groups: 1) 50 patients (age 59±12 years, 36 male) with severe asymptomatic MV regurgitation (regurgitant volume of ≥60 ml/beat with an effective regurgitant orifice area of ≥0.4 cm²). These patients were enrolled at the Centro Cardiologico Monzino, Milan; 2) 66 age-matched (45 M, age 55±11 years) normal (NL) subjects enrolled at the University of Chicago Hospitals, Chicago.

Exclusion criteria were: presence of 1) atrial fibrillation and cardiac arrhythmias, 2) ejection fraction (EF)<55% (biplane Simpson's rule from 2D transthoracic echocardiographic (TTE) data), 3) associated MV stenosis, 4) history of endocarditis or 5) coronary artery disease. Additional exclusion criteria for the normal subjects were: 1) abnormal regional LV function, 2) cardiac medications, 3) history of systemic hypertension and 4) valvular heart disease (MR more than mild).

2.2. Protocol

All patients underwent a complete 2D (S5 probe, Philips) and 3D TTE examination (X3-1 probe, Philips)

the day before, and at 6 and 12 months post MV repair. Post-repair, an intraoperative TEE was performed to assess for residual MR, mitral stenosis, and systolic anterior motion of the MV. In all cases, a ring annuloplasty was performed to stabilize the annulus and the suture line and the MV repair procedure was considered successful only when the grade of residual MR was less than or equal to mild. Patients with more than mild post repair MV regurgitation were excluded from the study. Normal subjects underwent a single 2D and 3D transthoracic study.

LV endocardial surfaces were semi-automatically obtained from RT3DE datasets using commercial software (4DLV Analysis, TomTec).

2.3. 3D LV shape analysis

Custom software implemented in the Matlab environment (MathWorks) was used to analyze the LV endocardial surfaces. Figure 1 briefly depicts the steps of this analysis, which were described elsewhere [4]:

- the LV surface was sampled along a helical pattern aligned with the LV long axis (LAX) from apex ($\theta=0$) to base ($\theta=1$), using 64 windings and 36 samples per winding;
- the obtained signal $s(\theta)$, describing the distance from the LAX to the endocardial surface, was normalized by LAX length leading to $s_{norm}(\theta)$;
- 3D shape indices were defined by measuring the degree of similarity between $s_{norm}(\theta)$, computed from the LV, and the signal $s_{ref}(\theta)$ obtained from a reference 3D shape. Spherical (S) and conical (C) shape indices were computed as:

$$\text{SHAPE INDEX} = 1 - A/A_{max}$$

where A is the area between the two signals $s_{norm}(\theta)$ and $s_{ref}(\theta)$, while A_{max} is the total area in the (s, θ) plane, equal to 0.5 by definition

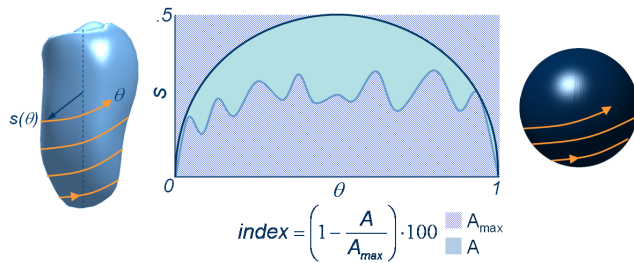


Figure 1. Schematic description of the computation of LV shape indices. The helical sampling of the LV endocardium is represented by the light blue line, while reference shape is shown by the dark blue line.

S and C indices were computed throughout the cardiac cycle and ranged between 0 and 1 by definition, with higher values corresponding to better similarity with the reference shape. These shape indices reflect LV shape

without being dependent on LV volumes.

2.4. Statistical analysis

In order to investigate the differences in functional and morphological parameters associated with MV repair, ANOVA for repeated measurements was performed ($p < 0.05$ was considered as significant).

Moreover, results from the MV group were compared using the unpaired t-test with those obtained from the control group, to test the degree of abnormality and its evolution at each time point in the study.

3. Results

None of the patients had intraoperative complications and residual MR was trivial or mild in all cases. As a result, no patients were withdrawn from the study.

Figure 2 shows an example of the pre and post-surgery ED apical 4-chamber views (top), depicting a reduction in LV following MV repair.

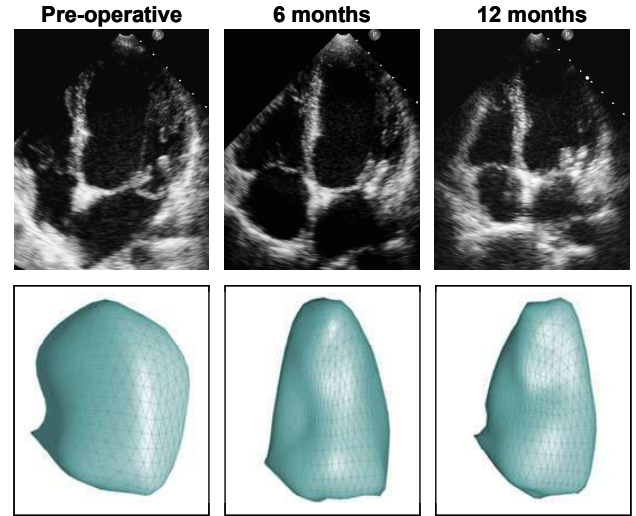


Figure 2. Example of end-diastolic 4-chamber views (top), and the corresponding LV endocardial surfaces (bottom) extracted from 3D TTE datasets in a patient undergoing MV repair, pre- (left) and 6 and 12 month post-MV repair (center and right, respectively), showing decreased LV volume associated with changes in LV shape at 6 and 12 months.

Table 1 presents the pre- and post-surgical measurements as well as the reference values obtained in the NL group for LV volumes and EF, both at end-diastole (ED) and end-systole (ES). Prior to surgery, LV volume at ED and EF were increased in the patients compared to the NL group. Six months post surgery, LV volumes were decreased compared to the pre-surgical values and these changes still persisted 1 year after surgery. In addition, EF decreased of 5% at 6 months,

while pre-surgical values were recovered after 1 year.

Table 1. Left ventricular end-diastolic (EDV) and end-systolic volumes (ESV) normalized for body surface area (BSA), and LV ejection fraction (EF) obtained in the normal group (NL) and for patients undergoing MV repair, pre and 6 and 12 months after surgery. * - $p < 0.05$ vs Pre, One-way ANOVA for repeated measures; § - $p < 0.05$ Pre vs NL, unpaired t-test.

	NL	Pre	6 months	12 months
EDV/BSA (ml/m ²)	63±12	73±22 [§]	54±13*	56±13*
ESV/BSA (ml/m ²)	28±7	28±10	24±8*	23±7*
EF(%)	57±5	61±6 [§]	56±6*	59±6

Figure 3 shows the results of LV shape indices obtained in MV repair patients at the different time points in the study, together with the corresponding normality range (mean ± 2SD, 95% confidence interval), computed from the NL group. Interestingly, despite the MV repair in patients with preserved EF, S and C indices measured prior to MV repair already showed higher (ED: $S=0.67±0.05$; ES: $S=0.59±0.04$) and lower (ED: $C=0.77±0.03$; ES: $C=0.82±0.02$) values, respectively, compared to age-matched normal subjects (ED: $S=0.61±0.03$, $C=0.80±0.02$; ES: $S=0.56±0.04$, $C=0.84±0.02$), both at ED and ES.

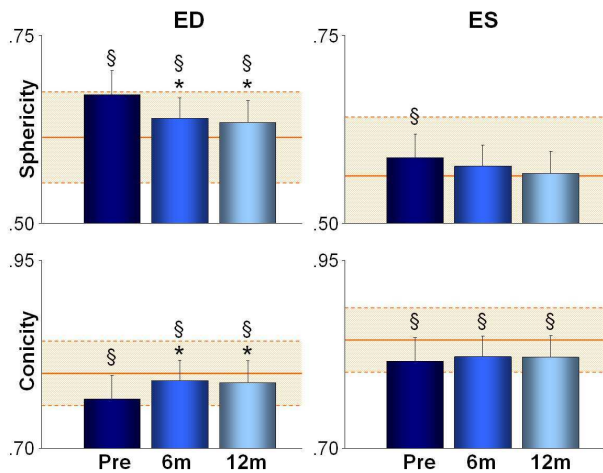


Figure 3. Bar graphs showing the results of LV sphericity (top) and conicity (bottom) indices, pre-, 6 and 12 month post MV repair, at end-diastole (ED, left) and at end-systole (ES, right). The shaded intervals in the background represent the reference range (mean±2SD). *: $p < 0.05$ vs Pre, One-way ANOVA for repeated measures; §: $p < 0.05$ vs NL, unpaired t-test.

Six months after MV repair, a decrease in S and an increase in C (ED: $S=0.64±0.05$, $C=0.79±0.03$) were evident at ED, with no further changes at 12 months (ED: $S=0.63±0.05$, $C=0.79±0.03$). A trend towards

normalization of LV shape was noted at 12 months despite the fact that these values were still slightly different from the NL range. In contrast, the comparison between pre- and post-surgery values showed no significant differences at ES. However, while the S index reached the NL range already after 6 months (ES: 6 months, $S=0.58±0.05$; 12 months: $S=0.57±0.05$), the C index remained outside the NL range (ES: 6 months, $C=0.82±0.03$; 12 months: $C=0.82±0.03$).

Figure 4 shows the changes in S and C at ED at each time point in the study in individual patients, with the NL range superimposed to better appreciate the improvement of these indices on an individual basis. For both S and C, pre-surgical values fell outside the NL range in 21/50 (42%) and 25/50 (50%) patients, respectively, and reflected more spherical and less conical LV shapes. Six months post surgery, the majority of patients showed S and C values within the NL range, resulting in only 13/50 (26%) and 10/50 (20%) patients outside the NL range. At 12 months, only 8/50 (16%) and 10/50 (20%) patients fell outside the NL range for S and C, respectively.

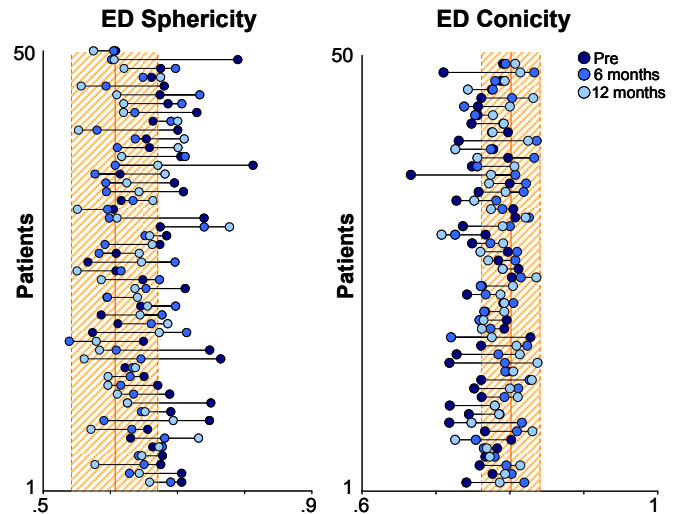


Figure 4. Results of the individual patterns of change for end-diastolic (ED) sphericity and conicity indices at each time interval (pre, black dots; 6 months, gray dots; 12 months, white dots). Normal ranges are depicted as shaded areas in the background (mean±2SD).

4. Discussion and conclusions

This is the first study to use volumetric shape analysis to serially study LV remodeling in patients with asymptomatic severe MR undergoing early MV repair. The main findings of this study were: 1) patients with asymptomatic severe MR due to MV prolapse and preserved LV function already exhibit changes in LV shape when compared to age-matched controls: LV

volumes and EF were higher in patients with MR compared to the control group; 2) 6 months post surgery, LV volumes and EF were lower than pre-surgical values, whereas at 12 months EF returned to pre-surgical levels while LV volumes remained unchanged; 3) these functional improvements were associated with favorable remodeling in LV shape from an abnormally spherical to a more normal conical shape; 4) transthoracic RT3DE, together with novel 3D shape analysis, allows a detailed examination of the complex pre- and post-surgical relationship between LV function and shape.

In clinical practice, LV shape has been correlated to exercise capacity [5] and prognosis in patients with either ischemic, idiopathic or dilated cardiomyopathy [6], as well as studied in patients undergoing LV remodeling post myocardial infarction [7] or used to predict the early recovery of LV function after aortic replacement [7]. Most of these clinical studies were performed with 2D echocardiography using several planar indices, heavily relying on geometric assumptions.

In this study, we applied a novel method to compute 3D LV shape from RT3DE datasets using sphericity and conicity indices. The main advantages of this technique are: 1) shape indices are computed directly from the 3D endocardial surface without the need for geometrical assumptions; and 2) the morphological evaluation is independent of LV volume.

It was previously demonstrated that the type of surgical procedure performed to correct chronic MR represents an important determinant on future LV function [9]. Specifically, LV systolic and diastolic function is preserved after MV repair, while MV replacement is associated with global and regional LV systolic dysfunction with early diastolic filling and relaxation abnormalities. In this study, we confirmed that early MV repair not only preserved LV systolic performance, despite a significant reduction of LV end-diastolic volumes, but was also associated with favorable geometric changes in its morphology.

This study has several limitations. First, LV shape analysis is dependent on the accuracy of LV endocardial border tracing, which in turn is dependent on image quality. Nevertheless, in this study, no patients were excluded for inadequate endocardial definition. Although shape analysis was performed throughout the cardiac cycle, only the ED and ES values for sphericity and conicity were reported. This is because the temporal resolution of the datasets was inhomogeneous and in some cases inadequate, precluding accurate temporal analysis.

This data reinforces the guidelines for the management of patients with MV disease, indicating that MV repair should be performed early in patients with asymptomatic MR, when clinically feasible, because this allows the

ventricle to restore its shape to near normal within 6 months.

References

- [1] Lee EM, Shapiro LM, Wells FC. Superiority of mitral valve repair in surgery for degenerative mitral regurgitation. *Eur Heart J.* 1997;18:655-63.
- [2] Enriquez-Sarano M, Schaff HV, Orszulak TA, Tajik AJ, Bailey KR, Frye RL. Valve repair improves the outcome of surgery for mitral regurgitation. A multivariate analysis. *Circulation.* 1995;91:1022-8.
- [3] Bonow RO, Carabello BA, Chatterjee K, de LA, Jr., Faxon DP, Freed MD, Gaasch WH, Lytle BW, Nishimura RA, O'Gara PT, O'Rourke RA, Otto CM, Shah PM, Shanewise JS. 2008 focused update incorporated into the ACC/AHA 2006 guidelines for the management of patients with valvular heart disease: a report of the American College of Cardiology/American Heart Association Task Force on Practice Guidelines. *J Am Coll Cardiol.* 2008;52:e1-142.
- [4] Maffessanti F, Lang RM, Corsi C, Mor-Avi V, Caiani EG. Feasibility of left ventricular shape analysis from transthoracic real-time 3D echocardiographic images. *Ultrasound Med Biol.* 2009 (in press).
- [5] Tischler MD, Niggel J, Borowski DT, LeWinter MM. Relation between left ventricular shape and exercise capacity in patients with left ventricular dysfunction. *J Am Coll Cardiol.* 1993;22:751-7.
- [6] Douglas PS, Morrow R, Ioli A, Reichek N. Left ventricular shape, afterload and survival in idiopathic dilated cardiomyopathy. *J Am Coll Cardiol.* 1989;13:311-5.
- [7] Mannaerts HF, van der Heide JA, Kamp O, Stoel MG, Twisk J, Visser CA. Early identification of left ventricular remodelling after myocardial infarction, assessed by transthoracic 3D echocardiography. *Eur Heart J.* 2004;25:680-7.
- [8] Matsumura Y, Gillinov AM, Toyono M, Wada N, Yamano T, Thomas JD, Shiota T. Usefulness of left ventricular shape to predict the early recovery of left ventricular function after isolated aortic valve replacement for aortic valve stenosis. *Am J Cardiol.* 2008;102:1530-4.
- [9] Corin WJ, Sutsch G, Murakami T, Krogmann ON, Turina M, Hess OM. Left ventricular function in chronic mitral regurgitation: preoperative and postoperative comparison. *J Am Coll Cardiol.* 1995;25:113-21.

Address for correspondence

Francesco Maffessanti, MS
Department of Biomedical Engineering, Politecnico di Milano
Piazza L. da Vinci 32, 20133 Milano, Italy
francesco.maffessanti@mail.polimi.it