

Effects of Frame Rate on 3D Speckle Tracking Based Measurements of Myocardial Deformation

Chattanong Yodwut^{1,2}, Lynn Weinert¹, Berthold Klas³, Roberto M. Lang¹, Victor Mor-Avi¹

¹University of Chicago, Department of Medicine, Chicago, Illinois, USA

²Ramathibodi Hospital, Mahidol University, Bangkok Thailand

³TomTec Imaging Systems, Unterschleissheim, Germany

Abstract

Myocardial strain has been shown useful in the evaluation of left ventricular (LV) function using 2D and 3D speckle tracking echocardiography (STE). 3D STE is potentially more accurate, because it is not affected by through-plane motion. While with 2D STE, high frame rates are necessary because speckles may move out of the imaging plane, we hypothesized that they should be tracked with 3D STE, even with lower frame rates, because they always remain within the scan volume.

Sixteen normal volunteers underwent 2D (at 62 ± 9 fps) and 3D imaging, which was performed at 4 different frame rates, achieved by varying the number of beats used for volume acquisition (6, 4, 2 and 1). The principal components of strain and the corresponding strain-rates were calculated from both 2D and 3D images.

Strain and strain-rates were the same for 3D STE with 6- and 4-beat datasets, corresponding to 25 and 18 fps, respectively, and were not significantly lower than 2D STE-derived values, indicating that there was no loss of information due to lower frame rates. In contrast, 3D STE with 1- and 2-beat datasets, corresponding to 5 and 10 fps, resulted in significantly lower values.

3D STE strains and strain-rates are not compromised by low frame rates, when derived from 18 or 25 fps datasets, but are underestimated with lower frame rates.

1. Introduction

Myocardial strain measured using tissue Doppler imaging and high frame rate two-dimensional (2D) speckle tracking echocardiography (STE) has been shown useful in evaluating left ventricular (LV) function [1]. Although real-time three-dimensional (3D) echocardiography (RT3DE) has in the past decade evolved as a useful modality for imaging of cardiac chambers and valves [2], and its ability to provide accurate estimates of LV volume throughout the cardiac cycle is well established, only few studies have attempted

3D assessment of LV deformation by using 3D measurements of myocardial strain [3-7]. These studies indicated that 3D STE may be more accurate than 2D STE in this context, because it is not affected by through-plane motion [6].

However, the relatively low frame rates of 3D STE are a potential limitation, which has not been studied to date. Specifically, there is a concern that 3D STE derived strain measurements may be underestimated because the frame rates of RT3DE are not sufficiently high to accurately capture all phases of the cardiac cycle. While it is understandable that with 2D STE, high frame rates are necessary because speckles may move out of the imaging plane and thus be lost, 3D STE may be able to track them even at considerably lower frame rates, as long as they remain within the 3DE scan volume. Accordingly, we hypothesized that comparable LV strain measurements could be obtained by 3D STE, despite the lower frame rates.

The present study was designed to test this hypothesis by evaluating the effects of frame rate on the 3D STE measurements of LV strain and strain-rate. The specific aims of this study were: (1) to compare measurements of the principal components of LV systolic strain and strain-rates obtained by 3D STE from full-volume datasets with different frame rates, (2) to determine the minimal frame rate that would result in strain and strain-rate values comparable with 2D STE measurements.

2. Methods

We studied 16 normal volunteers (8 males, age 45 ± 14 years) with good 2D and 3D echocardiographic image quality. Each subject underwent transthoracic 2D and 3D imaging at different frame rates to determine the minimal frame rate that would not result in a loss of strain information. To avoid analysis related differences, 2D and 3D STE analyses were both performed using software from the same manufacturer.

Imaging was performed using an iE33 imaging system and an X5 matrix-array transducer (Phillips). 2D imaging

included apical 2-, 3- and 4-chamber views as well as a short-axis view at the mid-papillary level. Imaging settings were selected to maximize frame rate, resulting in 62 ± 9 fps (43 to 88 fps). During 3D imaging, to ensure inclusion of the entire left ventricle within the pyramidal scan volume, datasets were acquired using the wide-angled full-volume mode during a single breath-hold. To allow 3D imaging at 4 different frame rates, the number of beats used for full-volume acquisition was varied, including 1, 2, 4 and 6 beats, corresponding to frame rates of 5 ± 1 , 10 ± 1 , 18 ± 2 and 25 ± 3 fps, respectively (fig. 1). The rest of the 3D imaging settings were kept unchanged throughout image acquisition.

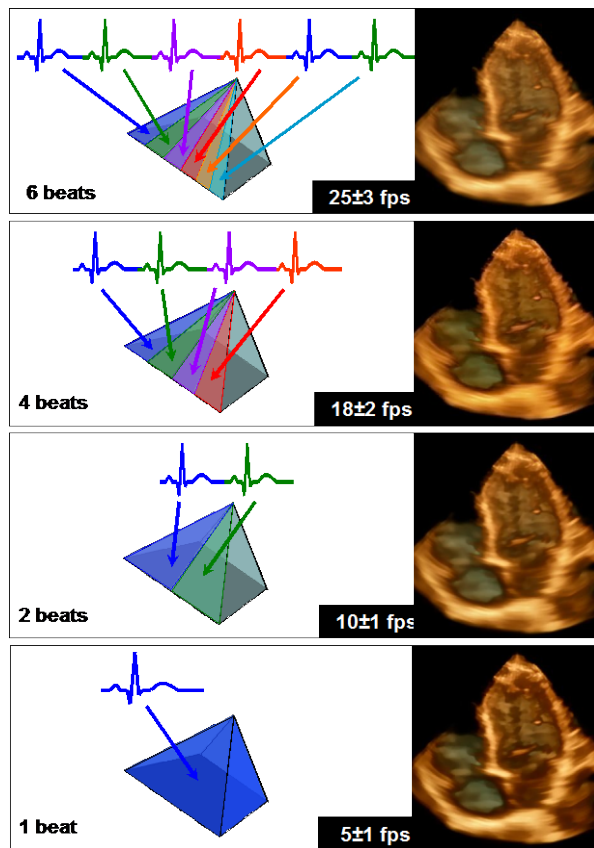


Figure 1. ECG-triggering over a different number of cardiac cycles: 1, 2, 4 or 6 (left) results in real-time 3D full-volume datasets with different frame rates (right).

3D images were analyzed using the 3D STE software (4D LV Analysis, TomTec). After the LV long axis was manually aligned in the three apical views (2-, 3-, and 4-chamber), the software automatically identified the LV endocardial border, while including the papillary muscles in the LV cavity, and tracked it throughout the cardiac cycle, resulting in a dynamic cast of the LV cavity. Endocardial contours were manually adjusted when necessary to optimize boundary tracking. Finally, time-curves of the 3 principal components of segmental

myocardial strain and the corresponding strain-rates were obtained using the standard 16-segment model. All time curves were interpolated resulting in effective temporal resolutions of 150-200 samples per second. For each strain component, peak segmental strain and strain-rate values were averaged over the 16 segments. These analyses were repeated for the 1-, 2-, 4- and 6-beat full-volume datasets by a reader who was blinded to all prior measurements.

2D images were analyzed to quantify segmental myocardial strain throughout the cardiac cycle using the 2D STE software (LV Analysis, TomTec). Apical 2-, 3- and 4-chamber views were used to obtain longitudinal and radial strain components and the corresponding strain rates in 16 myocardial segments (6 basal, 6 mid-ventricular and 4 apical), whereas the short-axis view was used to measure the circumferential component of strain and strain-rate in 6 segments. Peak segmental values were averaged for each strain component. 2D measurements were performed by the same reader, who was blinded to the 3D measurements.

For each peak strain and strain-rate, paired two-tailed student's t-tests were used to test differences between each type of acquisition (1-, 2- and 4- beats) against the 6-beat acquisition (i.e. highest frame rate). Then, paired two-tailed student's t-tests were used to test differences between the 6-beat acquisition and the 2D STE derived values. P-values < 0.05 were considered significant.

3. Results

Figure 2 shows examples of average segmental strain and strain-rate time curves obtained in a study subject. In each subject, the 3D STE derived strain time curves were similar in their shape to an LV volume curve. Of note, the radial strain curve was inverted, i.e. radial strain was positive throughout the cardiac cycle, reflecting systolic increase in myocardial thickness, while the longitudinal and circumferential strains were negative reflecting systolic shortening in these two dimensions.

Figure 3 shows average segmental peak longitudinal, circumferential and radial components of strain and strain-rates obtained by 3D STE from the 1-, 2- 4- and 6-beat full-volume datasets. Peak values of all strain components and the corresponding strain-rates were the same for 3D STE with 6- and 4-beat full-volume datasets (25 and 18 fps, respectively). In contrast, 1- and 2-beat datasets (5 and 10 fps), resulted in significantly lower strain and strain-rate values.

Longitudinal and radial strains and strain-rates obtained from 6- and 4-beat datasets using 3D STE were equal or higher than the 2D STE values (fig. 4), indicating that there was no loss of information due to lower frame rates. Circumferential strain and strain-rate were lower for 3D STE, but the difference did not reach statistical significance.

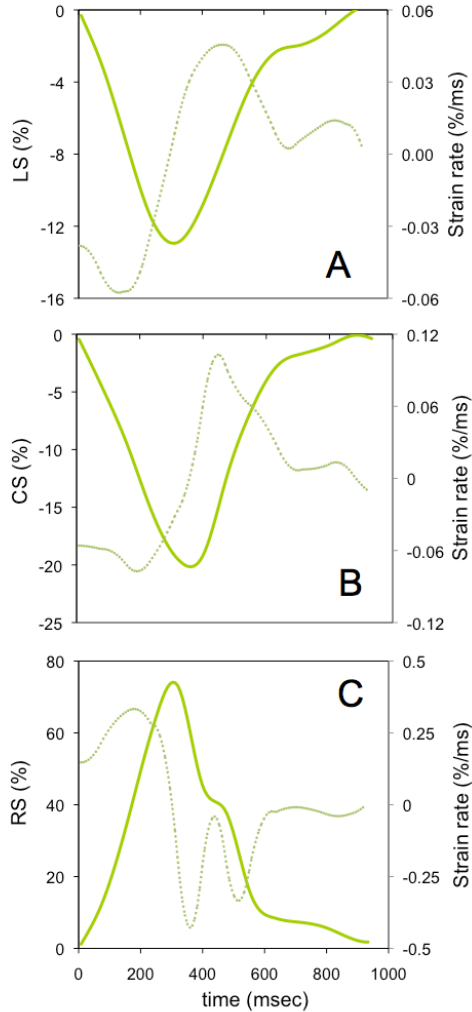


Figure 2. Example of mean segmental strains (solid lines) and the corresponding strain-rate (dotted lines) over time throughout the cardiac cycle, obtained in a normal subject using 3D speckle tracking (LS, CS, RS - longitudinal, circumferential and radial strains).

4. Discussion

To our knowledge, this is the first study to specifically address the issue of frame rate requirements for reliable 3D STE based measurements of myocardial deformation. Our study included only normal subjects with good image quality, as a way to minimize extraneous factors, such as regional variations in LV function, which would unnecessarily complicate the study and potentially hamper our ability to achieve its stated goals. Also, significant differences have been reported in strain measurements performed using software from different manufacturers [8,9]. To eliminate this factor, we analyzed both 2D and 3D images using analysis software from the same vendor.

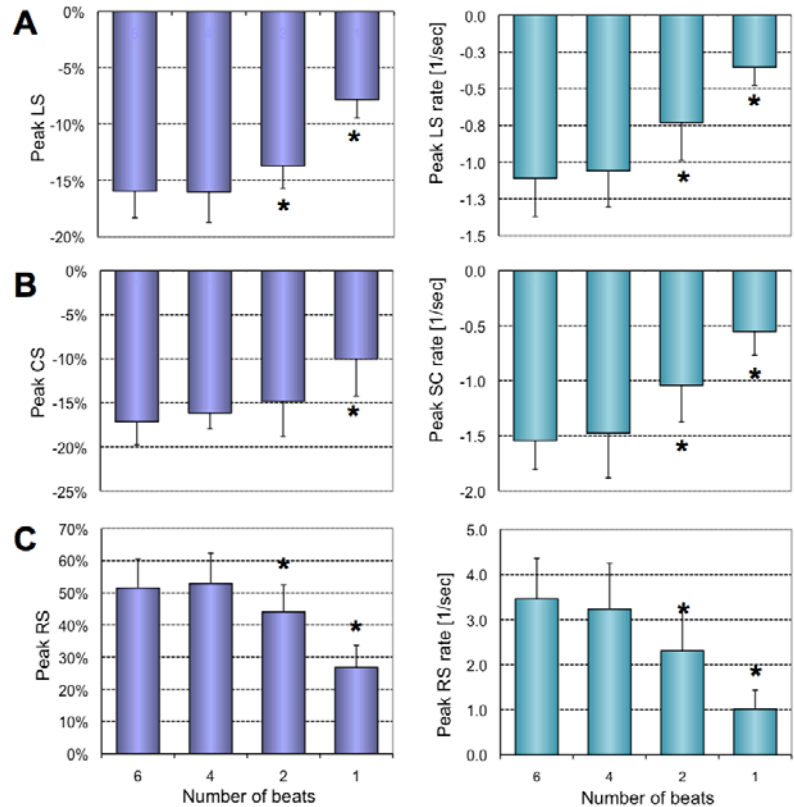


Figure 3. Results obtained in 16 normal subjects by 3D speckle tracking from 1-, 2-, 4- and 6-beat full-volume datasets for strain (left) and strain-rate (right): peak longitudinal, circumferential and radial strains (LS, CS, RS) and the corresponding strain-rates. * $p < 0.05$ compared to the 6-beat acquisition.

Importantly, strain and strain-rate values measured from 4- and 6-beat datasets (frame rates of 18 and 25 fps), were virtually the same for all three principal components. Further decrease in frame rates with the use of 1- and 2-beat datasets (5 and 10 fps), resulted in reduced magnitude of all strain components and the corresponding strain-rates. These findings indicate that loss of deformation information occurs somewhere between 10 and 18 fps, below which the frame rates are not sufficient to accurately capture all phases of the cardiac cycle. Importantly however, an increase in frame rates above 18 fps does not appear to provide any additional information regarding the magnitude of LV strain or strain-rate. This is contrary to considerably higher frame rates necessary to accurately measure strain or strain-rate from 2D images, in the 40-80 fps range [10].

We also found that 3D STE measurements of the three principal strain components and the corresponding strain-rates obtained from the 4- and 6-beat datasets were not significantly lower than their 2D STE counterparts. This

finding indicates that 3D STE frame rates as low as 18 fps reflect the magnitude of myocardial strain as accurately as the high frame rate 2D STE (62 ± 9 fps in this study), while lower frame rates are not sufficient to accurately capture all phases of the cardiac cycle, resulting in a loss of deformation information.

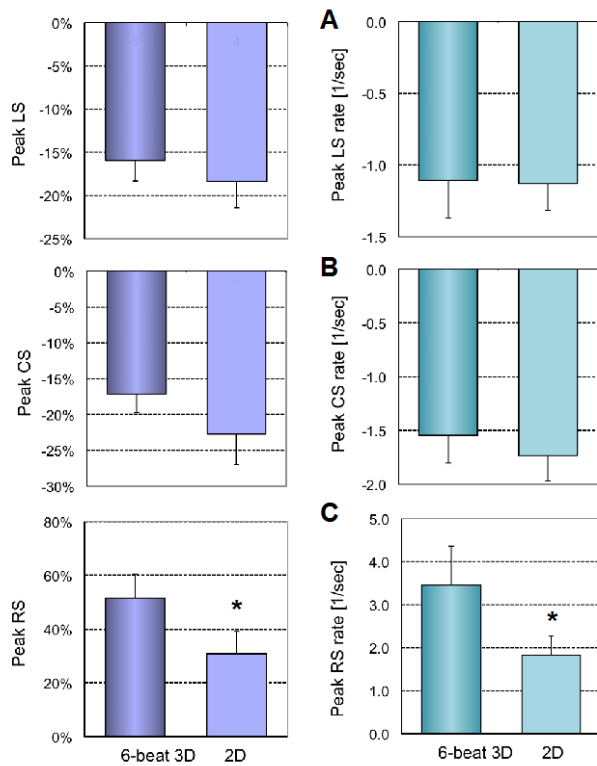


Figure 4. Results obtained in 16 normal subjects by 3D STE from the 6-beat full-volume datasets, corresponding to the highest frame rate, and by 2D STE: peak longitudinal (A), circumferential (B) and radial (C) strains (LS, CS, RS, respectively) and the corresponding strain-rates (right). * $p < 0.05$. See text for details.

One might view as a limitation of our study the lack of an independent reference technique to compare the 2D and 3D STE derived measurements. While 3D echocardiography derived regional LV volume time curves have been validated against cardiac magnetic resonance, as far as myocardial strain is concerned, there is no noninvasive “gold standard” technique that can be used in humans to validate it in three dimensions.

In conclusion, this is the first study to show that 3D STE allows quantitative analysis of myocardial deformation similar to the more established 2D STE techniques, despite the considerably lower frame rates. Importantly, this newer technique has the advantage of capturing the 3D nature of the complex ventricular systolic mechanics without the limitations imposed by through-plane motion.

Acknowledgements

Chattanong Yodwut, M.D., received a fellowship from the Department of Medicine, Ramathibodi Hospital, Mahidol University, Bangkok, Thailand.

References

- [1] Mor-Avi V, et al. Current and evolving echocardiographic techniques for the quantitative evaluation of cardiac mechanics: ASE/EAE consensus statement on methodology and indications. *J Am Soc Echocardiogr* 2011;24:277-313.
- [2] Mor-Avi V, et al. Real-time 3D echocardiography: An integral component of the routine echocardiographic examination in adult patients? *Circulation* 2009; 119:314-329.
- [3] De Isla LP, et al. Three-dimensional wall motion tracking: a new and faster tool for myocardial strain assessment: comparison with two-dimensional wall motion tracking. *J Am Soc Echocardiogr* 2009;22:325-30.
- [4] Seo Y, et al. Validation of 3-dimensional speckle tracking imaging to quantify regional myocardial deformation. *Circ Cardiovasc Imaging* 2009;2:451-9.
- [5] Saito K, et al. Comprehensive evaluation of left ventricular strain using speckle tracking echocardiography in normal adults: comparison of three-dimensional and two-dimensional approaches. *J Am Soc Echocardiogr* 2009;22:1025-30.
- [6] Maffessanti F, et al. Quantitative evaluation of regional left ventricular function using three-dimensional speckle tracking echocardiography in patients with and without heart disease. *Am J Cardiol* 2009;104:1755-62.
- [7] Kleijn SA, et al. Three-dimensional speckle tracking echocardiography for automatic assessment of global and regional left ventricular function based on area strain. *J Am Soc Echocardiogr* 2011;24:314-21.
- [8] Gayat E, et al. Reproducibility and inter-vendor variability of left ventricular deformation measurements by three-dimensional speckle-tracking echocardiography. *J Am Soc Echocardiogr* 2011;24:878-85.
- [9] Kaul S, et al. A suggested roadmap for cardiovascular ultrasound research for the future. *J Am Soc Echocardiogr* 2011;24:455-64.
- [10] Marwick TH, et al. Myocardial strain measurement with 2-dimensional speckle-tracking echocardiography: definition of normal range. *JACC Cardiovasc Imaging* 2009;2:80-4.

Address for correspondence.

Victor Mor-Avi
 University of Chicago Medical Center MC5084
 5841 S. Maryland Ave., Chicago, IL 60637, U.S.A.
 vmoravi@bsd.uchicago.edu