

Near-Automated Quantification of Prenatal Aortic Intima-Media Thickness from Ultrasound Images

G Tarroni¹, S Visentin², E Cosmi², E Grisan¹

¹University of Padova, Padova, Italy

²University Hospital of Padova, Padova, Italy

Abstract

Aortic intima-media thickness (aIMT) is an early marker for atherosclerosis and cardiovascular diseases risk assessment in children and young adults. Recent studies have underlined the potential usefulness of its estimation at the fetal stage from ultrasound (US) images. However, this measurement currently relies on tedious and error-prone manual tracing. The aims of this study were to develop and test a near-automated technique for aIMT quantification from US images. The proposed technique is based on narrow-band level-set methods to identify blood-intima and media-adventitia interfaces, thus allowing aIMT estimation. The technique was tested on images acquired from 11 subjects at a mean gestational age of 29 weeks. Automatically estimated aIMT values were compared to reference ones manually extracted by an experienced interpreter. Quantitative comparisons were performed using Pearson's correlation coefficients, Bland-Altman and linear regression analyses. The results (R up to 0.92) indicate the high correlation between automatically and manually estimated values, suggesting that near-automated quantification of aIMT from US images using level-set methods is feasible.

1. Introduction

Following Barker's hypothesis [1], many recent studies have suggested the occurrence of programming of several diseases during fetal life. More in particular, it has been shown that low birth weight, caused either by preterm birth or fetal growth restriction (FGR), is associated with increased rates of cardiovascular diseases (e.g. atherosclerosis) and metabolic disorders (e.g. non-insulin dependent diabetes) in adulthood [2]. Children who were affected by FGR during gestation have thicker aortic walls, indicating that adverse prenatal conditions might be associated with structural changes in the main vessels [3], [4]. Therefore, the intima-media thickness of the abdominal aorta (aIMT) has become an early marker

for the quantitative assessment of atherosclerosis risk in children. Recent studies [5] indicate that vascular structure alterations due to FGR could be identified already at the fetal stage from ultrasound (US) images, allowing risk assessment for atherosclerosis and cardiovascular diseases during gestation. Unfortunately, aIMT estimation from US images relies on tedious, error-prone and operator-dependent manual tracing.

Our goal was to develop a near-automated technique for the quantification of aIMT from US images. The proposed approach relies on narrow-band region-based level-set methods to identify blood-intima and media-adventitia interfaces as a basis for aIMT estimation. The technique was tested against manual analysis by means of Pearson's correlation coefficients, Bland-Altman and linear regression analyses.

2. Methods

2.1. Image analysis

The proposed technique allows the near-automated estimation of aIMT from fetal US images. The main steps of the technique are the following ones: A) aortic lumen identification, B) intima-media region segmentation, and C) intima-media thickness estimation.

A) Aortic lumen identification. The only manual input required from the user is the selection of a region-of-interest (ROI) containing the abdominal aorta (Fig. 1, left). A thresholding process based on Otsu's method [6] is applied to the portion of the image contained in the ROI. The result consists of a coarse segmentation of the aortic lumen as well as of other potential regions. To select the aortic lumen, area and eccentricity of the best fitting ellipses are extracted from each segmented region: the lumen is identified as the biggest region among the four with higher eccentricity (Fig. 1, right). Of note, the aortic lumen identification step is only required to correctly initialize the following intima-media region segmentation step, and thus does not require a high level of accuracy.

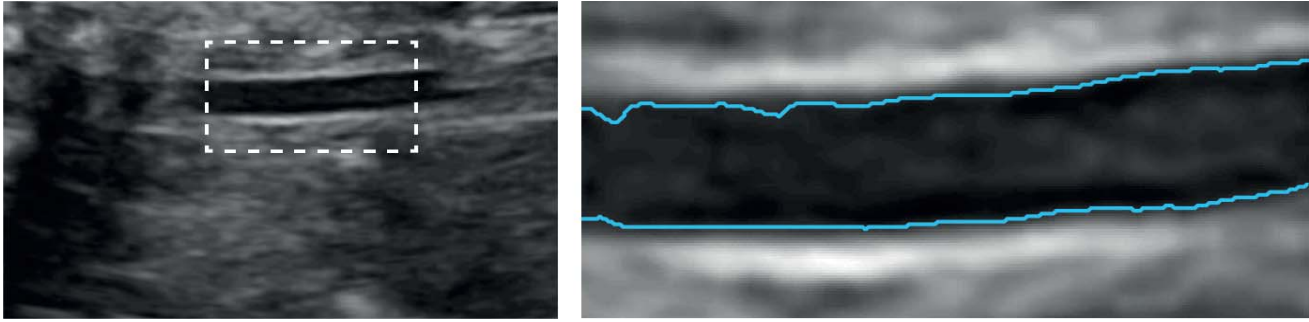


Figure 1. Fetal US image showing the abdominal aorta (left). The user is asked to manually select a ROI containing the vessel (left, dashed line). Automated detection of the aortic lumen is then performed (right, cyan).

B) Intima-media region segmentation. Abdominal aIMT is defined as the average thickness of the region between the leading edge of the blood-intima interface and the leading edge of the media- adventitia interface on the far wall of the vessel [7]. In the proposed approach both of these regions - one in the upper portion of the image (defined as upper wall) and one in the lower portion (defined as lower wall) - are segmented using a single level-set. Initialization is performed starting from the previously identified aortic lumen: a thresholding process is applied to the two band-like portions of the image surrounding the lumen (Fig. 2, left, cyan). The thickness (in px) of these portions is defined by an arbitrary parameter. Since both tunica intima and tunica media appear bright in US images, the thresholding process allows a first identification of the intima-media regions (Fig. 2, left, yellow). The level-set function is defined as the signed distance function from these portions, and undergoes an evolution in time in order to minimize a specific energy functional in a narrow-band approach [8]. The energy functional E is written as

$$E(\phi) = \int_{\Omega_x} \delta(\phi(x)) \int_{\Omega_y} B(x, y) F(I(y), \phi(y)) dy dx$$

where ϕ is the level-set function, Ω is the image domain, $\delta(\phi)$ is a smoothed version of the Dirac delta, B is the ball mask function which allows to implement the narrow-band approach and F is a generic internal energy measure computed on the image intensity I . B is defined as

$$B(x, y) = \begin{cases} 1, & \|x - y\| < r \\ 0, & \|x - y\| \geq r \end{cases}$$

where r is a fixed parameter, and allows to evaluate the functional F locally around each contour point. The choice for F adopted in the proposed technique is the Means Separation Energy [9], which reads as

$$F = (u_x - v_x)^2$$

where u_x and v_x are respectively the inner and outer

mean intensity values, with respect to the contour, evaluated inside the mask function B . The evolution is carried out with suitable boundary conditions and is automatically stopped when the variation in area of the segmented regions between consecutive iterations becomes negligible (Fig. 2, right). At the end of the level-set evolution, there can be potentially more than one segmented region for each wall. In order to select only one, ellipses are fitted into each region, and the one with the highest associated eccentricity is selected (for each wall) for aIMT estimation.

C) Intima-media thickness estimation. aIMT estimation is achieved separately for the upper and lower wall by identifying the central line of the region (through a skeletonization process) and by fitting circles in the region itself (with central points taken from each point of the central line): the aIMT value is then estimated computing the mean diameter of the fitting circles.

2.2. Image acquisition

Image acquisition was performed on eleven subjects undergoing routine US examinations during pregnancy. The local ethical committee approved the study and all patients gave written informed consent. Fetal US data was acquired at a mean gestational age of 29 weeks (range 20 to 34 weeks) using a US machine equipped with a 5 MHz linear array transducer (Voluson E8, GE, General Electric Company, Fairfield, CT), with a 70° FOV, image dimension 720x960 px and a variable resolution between 0.05 and 0.1 mm. The localization of the abdominal aorta was performed in a sagittal view of the fetus at the dorsal arterial wall of the most distal 15 mm of the abdominal aorta, sampled below the renal arteries and above the iliac arteries. Gain settings were tuned to optimize image quality. After localization, the vessel was visualized in a maximal longitudinal section (thus containing the vessel diameter) and tilting the transducer to obtain an angle of insonation as close to 0° as possible and always less than 30°.

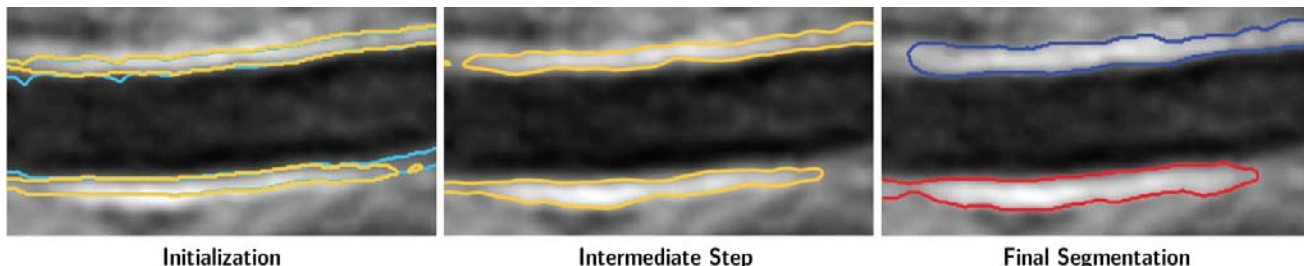


Figure 2. Intima-media region segmentation. Starting from two bands of fixed thickness defined surrounding the previously identified aortic lumen (left, cyan), thresholding is performed to define initial masks for the level-set function (left, yellow). A narrow-band level-set method drives the evolution of the contours (center, yellow). At convergence, at least one region per aortic wall is identified (right, blue and red for upper and lower wall, respectively).

2.3. Performance testing

To evaluate the performance of the proposed technique, an experienced interpreter manually analyzed the acquired sequences. From each of the 11 sequences, the interpreter selected 4 frames (for a total of 44 images) depending on the visibility of the aortic walls, and then manually traced the blood-intima and media-adventitia interfaces on each image, providing aIMT estimation on both the upper and lower wall, separately. The proposed technique was then applied to the same images, performing near-automated aIMT quantification. Of note, the parameter for the intima-media region segmentation step was heuristically set to 8 px and kept constant for all the images. To obtain more reliable estimates for the aIMT, the measurements (for both the automated and manual analyses) were averaged on the 4 frames belonging to each sequence, allowing a subject-based quantification for each of the two walls. Pearson's correlation coefficients, linear regression and Bland-Altman analyses were performed between the aIMT values obtained automatically and manually.

3. Results

Time required to perform the automated aIMT estimation for both walls (starting from the user-defined ROI) was around 25 s on a laptop using code implemented in MATLAB (The Mathworks, Natick, MA) with no parallelization implemented yet.

Fig. 3 shows some examples of visual comparisons between the results of the automated and manual identification of the blood-intima and media-adventitia interfaces in images acquired from different subjects.

The quantitative results for Pearson's correlation coefficients and linear regression analyses between automatically and manually extracted aIMT values for each wall are reported in Table 1. Bland-Altman analyses results are reported in Table 2. Of note, on one of the 11 image sequences the automated analysis could not be

correctly performed on the lower wall (potentially due to image degradation), and thus the obtained values were not included in the quantitative comparisons.

aIMT	R	a	b
Upper Wall	0.92	0.89	-0.26
Lower Wall	0.79	0.64	0.29

Table 1. Results for the Pearson's correlation coefficients and linear regression analyses between automatically and manually extracted aIMT values for both walls (R and a are dimensionless, b is in mm).

aIMT	Bias	Std	Mean Value
Upper Wall	-0.03	0.09	0.75
Lower Wall	-0.03	0.10	0.75

Table 2. Results of the Bland-Altman analyses between automatically and manually extracted aIMT values for both walls (all values are in mm).

4. Discussion and conclusions

Intima-media thickness of the abdominal aorta is a widely accepted early marker for the quantitative assessment of atherosclerosis risk in children and young adults. Although recently several studies have suggested the importance of its assessment during the fetal stage, to the best of our knowledge there is only one preliminary work addressing the issue of automated aIMT estimation from fetal US images [10].

In the present study, we developed a novel near-automated technique for aIMT estimation from fetal US images, and we tested it against manual tracing. In the proposed approach, the user is asked only to manually select a ROI containing the abdominal aorta. The technique uses narrow-band level-set methods to automatically segment regions between the blood-intima and media-adventitia interfaces, from which the estimation of aIMT is performed.

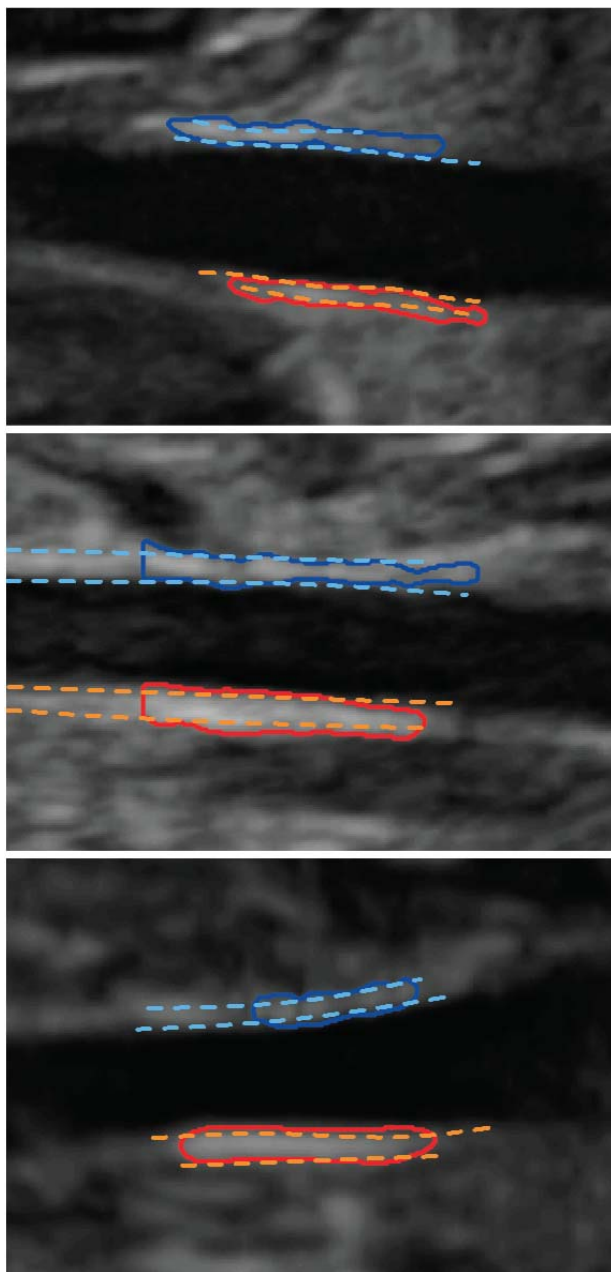


Figure 3. Comparisons between intima-media regions identified using the proposed technique (blue and red solid lines) and by manual analysis (cyan and orange dashed lines) on images acquired from different subjects.

The obtained results show the good agreement between automatically and manually extracted aIMT values, as indicated by small biases and narrow limits of agreement with respect to the mean measured values. A high degree of correlation was obtained between automatically and manually estimated values: of note, correlation was higher for the upper wall ($R = 0.92$) than for the lower wall ($R = 0.79$), potentially due to loss of definition of the

blood-intima and media-adventitia interfaces in that portion of the image.

In conclusion, near-automated estimation of aIMT from fetal US images using narrow-band level-set methods is feasible, and could provide a valuable alternative to tedious and subjective manual analysis.

References

- [1] Barker DJP. Maternal nutrition, fetal nutrition, and disease in later life. *Nutrition* 1997;13:807–813.
- [2] Hemachandra AH, Howards PP, Furth SL, Klebanoff MA. Birth weight, postnatal growth, and risk for high blood pressure at 7 years of age: results from the Collaborative Perinatal Project. *Pediatrics* 2007;119:e1264–e1270.
- [3] Litwin M, Niemirska A. Intima-media thickness measurements in children with cardiovascular risk factors. *Pediatr Nephrol* 2009;24:707–19.
- [4] Crispi F, Bijnens B, Figueras F, Bartrons J, Eixarch F, Le Noble F, Ahmed A, Gratacós E. Fetal growth restriction results in remodeled and less efficient hearts in children. *Circulation* 2010;121:2427–36.
- [5] Cosmi E, Visentin S, Fanelli T, Mautone AJ, Zanardo V. Aortic intima media thickness in fetuses and children with intrauterine growth restriction. *Obstet Gynecol* 2009;114:1109–1114.
- [6] Otsu N. A threshold selection method from gray-level histograms. *IEEE Trans Syst Man Cybern* 1979;9:62–66.
- [7] Koklu E, Kurtoglu S, Akcakus M, Yikilmaz A, Coskun A, Gunes T. Intima-media thickness of the abdominal aorta of neonate with different gestational ages. *J Clin Ultrasound* 2007;35:491–497.
- [8] Lankton S, Tannenbaum A. Localizing region-based active contours. *IEEE Trans Image Process* 2008;17:2029–39.
- [9] Yezzi A, Tsai A, Willsky A. A fully global approach to image segmentation via coupled curve evolution equations. *J Vis Commun Image Represent* 2002;13:195–216.
- [10] Veronese E, Poletti E, Cosmi E, Grisan E. Estimation of prenatal aorta intima-media thickness in ultrasound examination. *SPIE Medical Imaging* 2012:83150M.

Address for correspondence:

Giacomo Tarroni, PhD
 University of Padova
 Via G. Gradenigo 6/B, 35131 Padova, Italy
 giacomo.tarroni@dei.unipd.it