

Defining Angular and Radial Positions and Parameters for Myocardial Pixels in Cardiac MR Images

Kjersti Engan¹, Leik Woie², Trygve Eftestøl¹

¹ University of Stavanger, Dep. of electrical eng. and comp. science, Stavanger, Norway,

² Stavanger University Hospital, Stavanger, Norway

kjersti.engan@uis.no

Abstract

In this work we aimed to automatically produce a measure for the angular and radial position of all pixels within the myocardium in CMR images, left ventricle, short axis view. A reference axis is chosen in an anatomically meaningful way, and this makes the angular position measure easy to relate to the American Heart Association (AHA) 17 segment model. The angular and the radial position give values for each pixel so that each pixel can be represented by a 3D vector of information [intensity value, angular position, radial position]. Using this 3D representation of each pixel, interesting parameters can easily be defined. For example looking at LGE-CMR images for patients with myocardial scar, parameters for describing the localization of the scar segments can be found automatically and objectively, and can be used for further classification of patients.

1. Introduction

After a myocardial infarction there will be scarred tissue in the myocardium. Late Gadolinium Enhanced Cardiac Magnetic Resonance (LGE-CMR) imaging is a technique using a contrast agent (gadolinium) to make the scarred areas visible on the MR images. The contrast agent will firstly spread in all the myocardial tissue, but will be washed out more slowly in areas with no or little blood circulation. Thus these areas will appear bright on the LGE-CMR images. It is known that the size of the scar is important for further treatment of the patients, and also the localization of the scar. The localization of the scar depends on which artery was the cause of the infarction. Some parameters describing the scar size and localization are found today mostly by use of manually or semiautomatic methods that requires human interaction.

In this work we aimed to automatically produce a measure for the angular and radial position of all pixels within the myocardium in LGE-CMR images, left ventricle, short

axis view. This can be used in combination with scar segments from myocardial infarctions defining new parameters of interest, easily and objectively computed. The input as presented in this paper is the endocardial and epicardial borders, as well as the scar segments. All can be found by either manual or automatic methods.

There have been attempts to solve the segmentation of myocardium in LGE-CMR images automatically. Some methods require manual input in the form of landmarks or cropping of region of interest, etc [1, 2]. Others make use of additional data as the corresponding CINE MR [3–5], or a combination of cine images and some manual input [6]. Others are segmenting based on the LGE-CMR images alone [7, 8]. We expect that these type of methods will be good enough to do the segmentation automatic in the (near) future.

There are different approaches for automatic segmentation of the scarred areas found in the literature as well. Some examples can be found in [9–11].

2. Proposed method

The proposed method is general, but the data material that initiated this work, and that is used in figure 4 is LGE-CMR images, left ventricle, short axis view, of patients with myocardial infarction provided by The Department of Cardiology at Stavanger University Hospital. LGE-CMR was performed using 1.5 T Philips Intera R 8.3, pixel size of typically $0.82 \times 0.82\text{mm}^2$, covering the whole left ventricle with short-axis slices of 10 mm thickness, without inter-slice gaps.

2.1. Heart Axis HA_s

Let $x_s(i, j)$ correspond to the pixel intensity value at a position (i, j) , i.e. row i and column j , at slice s . The set of pixel positions, $\{(i, j)\}$, of slice s between the endocardial and epicardial border corresponds to the set of pixel positions in the myocardial muscle, and is called \mathcal{M}_s .

$$x_{M_s}(i, j) = \begin{cases} x_s(i, j) & \forall (i, j) \in \mathcal{M}_s \\ \text{NaN} & \forall (i, j) \notin \mathcal{M}_s \end{cases} \quad (1)$$

defines the CMR image of slice s , x_{M_s} , where all the pixels values in positions outside the myocardium is set to NaN. Lets define a mask image for slice s as M_s :

$$M_s(i, j) = \begin{cases} 1 & \forall (i, j) \in \mathcal{M}_s \\ 0 & \forall (i, j) \notin \mathcal{M}_s \end{cases} \quad (2)$$

Now we can define the center of the myocardium as a point P_{cm_s} with coordinates (i_{cm_s}, j_{cm_s}) :

$$P_{cm_s} = \text{centroid}(M_s) = (i_{cm_s}, j_{cm_s}) \quad (3)$$

Since we are going to define localization parameters, an absolute reference is needed. A heart axis HA_s is defined in each slice s as the axis from the center of the myocardium, P_{cm_s} through a point where the left and right ventricle coincide, $P_{LRV_s} = (i_{LRV_s}, j_{LRV_s})$. In present work we have used a manually marked point where the left and right ventricle coincides in the slices with visible right ventricle. P_{LRV_s} can be found automatically in future work. In slices where the right ventricle is not visible, we have used the same point as for the closest slice with a visible right ventricle. The heart axis is shown in figure 1 for illustration, and is also marked in Figure 4 on a real image.

2.2. Angular position

We want to define an angular position value, $\phi_s(i, j)$, for every position $(i, j) \in \mathcal{M}_s$. Firstly the radial axis, $RA_{M_s}(i, j)$ is defined as an axis from P_{cm_s} through pixel position $(i, j) \in \mathcal{M}_s$. The previously mentioned heart axis is called HA_s . The angular position for every pixel position $(i, j) \in \mathcal{M}_s$ is then defined:

$$\phi_s(i, j) = \angle(HA_s, RA_{M_s}(i, j)), \forall (i, j) \in \mathcal{M}_s \quad (4)$$

where $\angle(a, b)$ gives the angle from a to b in a counter clockwise direction, and $\phi_s(i, j) \in [0, 2\pi]$. The angular position as well as the heart axis HA_s and the radial axis are illustrated in Figure 1.

The choice of using P_{LRV_s} , the point where the left and right ventricle coincides, as reference was done to be sure it refers to an anatomical meaningful point that is possible to find in all patients, and also it makes the comparison with the American Heart Association (AHA) 17 segment model very easy [12]. The same axis, going through P_{LRV_s} and P_{cm_s} , the center of the heart, is marking the border between segment 3 and 4 in the *Basal region* as well as segment 9 and 10 in the *Mid-ventricular region* in the AHA 17 segment model. Thereafter all the segments

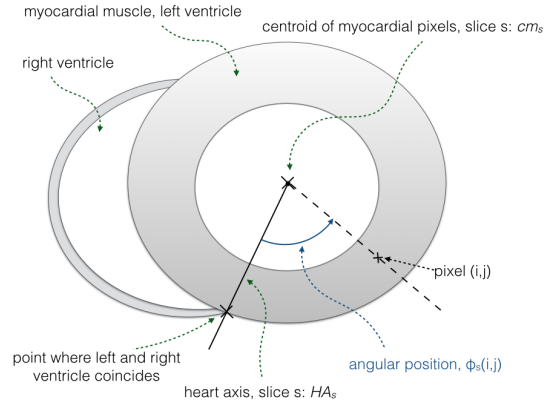


Figure 1. Angular position, $\phi_s(i, j)$ is illustrated as well as the heart axis, HA_s . The radial axis $RA_{M_s}(i, j)$ is seen as the dashed line going from the center of the myocardium, P_{cm_s} , through the pixel at position $(i, j) \in \mathcal{M}_s$.

in these two regions are given a Δ angle of $\frac{\pi}{3}$. The *Apical region* is divided differently with four regions, each with a Δ angle of $\frac{\pi}{2}$. The border between segment 14 and 15 in the *Apical region* must be shifted with $\frac{-\pi}{12}$, i.e. $\frac{\pi}{12}$ in a clockwise direction, compared to the defined heart axis, HA_s , see Figure 2. In our dataset the *Apex*, segment 17 of the AHA model, was not given a separate slice, thus the *Apex* was considered to be divided into the segments of the *Apical region*. These are implementation details that does not change the principle of the localization parameters.

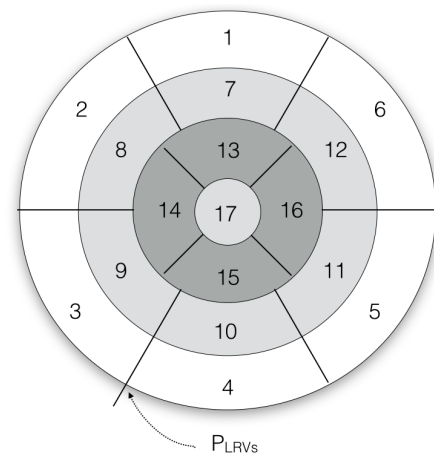


Figure 2. AHA 17 segment model with the P_{LRV_s} marked.

2.3. Radial position

We want to define a value $\lambda_{M_s}(i, j)$ called radial position for all the pixels in the myocardium, i.e. for all the

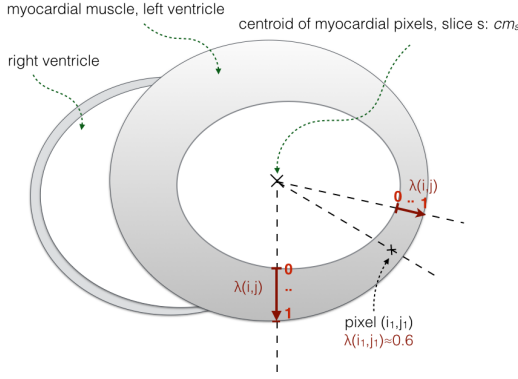


Figure 3. Radial position, $\lambda_s(i, j)$ is illustrated. Three examples of radial axis $RA_{M_s}(i, j)$ are seen as the dashed lines. On each axis the radial position is defined from 0 to 1 for each pixel inside the myocardial borders.

pixel positions $(i, j) \in \mathcal{M}_s$. Since the image is discrete an approximation is needed. A small segment is defined as:

$$S_k = \{(i, j)\} \in \mathcal{M}_s \text{ such that } \phi_{s_{k-1}} < \phi_s(i, j) < \phi_{s_k}. \quad (5)$$

A distance measure from the position of the centroid, P_{cm_s} to all pixels $(i, j) \in S_k$ is found:

$$d_k(i, j) = \sqrt{(i - i_{cm_s})^2 + (j - j_{cm_s})^2} \quad \forall (i, j) \in S_k \quad (6)$$

The set of distance measures in the segment S_k is defined:

$$d_k^{S_k} = \{d_k(i, j)\} \quad \forall (i, j) \in S_k. \quad (7)$$

The following normalization ensures that all radial positions are given a value $\lambda_s(i, j) \in [0, 1]$:

$$\lambda_s(i, j) = \frac{(d_k(i, j) - \min(d_k^{S_k}))}{(\max(d_k^{S_k}) - \min(d_k^{S_k}))} \quad (8)$$

Now $\lambda_s(i_l, j_l) = 0$ always means that the position (i_l, j_l) is located on the endocardial border, and correspondingly $\lambda_s(i_m, j_m) = 1$ means that the position (i_m, j_m) is located on to the epicardial border, independent of the changes in the thickness of the myocardial wall. The radial position, $\lambda_s(i, j)$ is illustrated in Figure 3.

Now all pixels in the myocardium can be represented by a three dimensional vector $\mathbf{p}_s(i, j) = [x_s(i, j) \quad \lambda_s(i, j) \quad \phi_s(i, j)]$, $(i, j) \in \mathcal{M}_s$. This is illustrated with the example image in figure 4.

3. Defining Parametres

Interesting parameters in the myocardium can easily be found by use of the vector $\mathbf{p}_s(i, j)$ This work is focused on

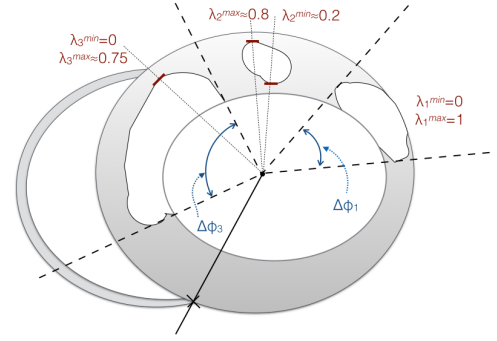


Figure 5. Schematic example of a myocardial slice with three scar segments. λ_l^{min} and λ_l^{max} are indicated for all three segments. $\Delta\phi_l$ is indicated for segment 1 and 3.

LGE CMR images from patients with a myocardial scar, and thus define parameters regarding the scar. However $\mathbf{p}_s(i, j)$ can be used to define other parameters regarding other types of visible segments in the myocardium, or to characterize the myocardial muscle (e.g. distribution of wall thickness, etc.).

A patient that has had a myocardial infarction has scarred tissue in the myocardium. Segmenting the scarred tissue from the healthy tissue is not dealt with here, but this can be done manually (by cardiologists) or automatically by different methods [10], [11]. Using automatic methods will normally give a more fragmented scar with some small segments, whereas a manual marking can give only one segment, but might also give a couple of different scar segments. Thus no matter if a manual or automatic method is used each slice might have a different number of smaller or bigger scar segments. In the following a scar segment is considered to be connected pixels (8 neighborhood), with minimum size of two pixels marked as scar by the applied method.

For all scar segments in slice s we define $\Delta\phi_{s_l}$ as the value in radians of the smallest angle (sector) containing all the pixels defined as scar segment l . $\lambda_{s_l}^{min}$ is defined as the smallest λ value of all the pixels in scar segment no. l , and $\lambda_{s_l}^{max}$ is defined as the largest λ value of all the pixels in scar segment no. l . Lets define:

$$\Delta\lambda_{s_l} = \lambda_{s_l}^{max} - \lambda_{s_l}^{min} \quad (9)$$

for scar segment l at slice s as another important parameter that can be used for example when describing transmural-ity of the scar.



Figure 4. Left: Myocardial slice s with marked heart axis, HA , (solid line) and angular borders of two scar segments (dotted lines). Middle: corresponding angle (ϕ_s) values. Right: λ_s values for the shown slice.

4. Conclusion and future work

Defining the endocardial and epicardial borders of the myocardium can be done manually or (semi) automatically, and so can defining the point P_{LVR_s} and segmenting scarred tissue in the myocardium. After the definition of these segments and points, the angular and radial position can be found automatically for each pixel position in the myocardium. The resulting 3D vector $\mathbf{p}_s(i, j) = [x_s(i, j) \ \lambda_s(i, j) \ \phi_s(i, j)]$, $(i, j) \in \mathcal{M}_s$ for each pixel in the myocardium makes it easy to define interesting parameters and to quantify scars according to the AHA 17 segments model if wanted. In future work we will explore localization parameters regarding transmuralty of scar and angular position of scars compared to which artery was clogged prior to infarction. Different parameters will be tested in a classifier setting when classifying high risk from low risk patients considering implantable cardioverter defibrillator treatment.

References

- [1] Spreeuwens L, Breeuwer M. Detection of left ventricular and epi- and endocardial borders using coupled active contours. In Proc. Comput. Assisted Radiol. Surg. 2003; 11471152.
- [2] Heiberg E, Sjgren J, Ugander M, Carlsson M, Engblom H, Arheden H. Design and validation of segment a freely available software for cardiovascular image analysis. In BMC Medical Imaging, volume 10:1. 2010; .
- [3] ODonnell T, Xu N, Setser R, White R. Semi-automatic segmentation of nonviable cardiac tissue using cine and delayed enhancement magnetic resonance images. In Proceedings of SPIE 2003, volume 5031. 2003; 242.
- [4] Ciofolo C, Fradkin M, Mory B, Hautvast G, Breeuwer M. Automatic myocardium segmentation in late-enhancement MRI. In Proceedings of IEEE International Symposium on Biomedical Imaging (ISBI). 2008; .
- [5] Wei D, Sun Y, Ong S, Chai P, Teo LI, Low AF. Three-dimensional segmentation of the left ventricle in late gadolinium enhanced mr images of chronic infarction combining long- and short-axis information. Medical Image Analysis 2013;17(6):685–697. Doi:10.1016/j.media.2013.03.001.
- [6] Dikici E, ODonnell T, Setser R, White R. Quantification of delayed enhancement MR images. In Proceedings of the International Conference on Medical Image Computing and Computer-Assisted Intervention. 2004; 250–257.
- [7] Alba X, i Ventura RF, Lekadir K, Tobon-Gomez C, Hoogendoorn C, Frangi A. Automatic cardiac lv segmentation in MRI using modified graph cuts with smoothness and interslice constraints. Magnetic Resonance in Medicine 2013; Doi: 10.1002/mrm.25079.
- [8] K.Engan, Naranjo V, Eftestøl T, Ørn S, Woie L. Automatic segmentation of the epicardium in late gadolinium enhanced cardiac MR images. In Proc. of Computing in Cardiology 2013. Zaragoza, Spain, September 2013; .
- [9] Tao Q, Milles J, Zeppenfeld K, et al. Automated segmentation of myocardial scar in late enhancement mri using combined intensity and spatial information. Magnetic Resonance in Medicine 2010;64:586–594.
- [10] Kotu L, Engan K, Skretting K, Ørn S, Woie L, Eftestøl T. Segmentation of scarred myocardium in cardiac magnetic resonance images. ISRN Biomedical Imaging Hindawi 2013;Article ID 504594, doi: 110.1155/2013/504594.
- [11] Woie L, Måløy F, Eftestøl T, K.Engan, Edvardsen T, Kvaløy J, S.Ørn. Comparing a novel automatic 3D method for LGE-CMR quantification of scar size with established methods. The International Journal of Cardiovascular Imaging 2014;30:339–347. Doi: 10.1007/s10554-013-0329-0.
- [12] Cerqueira MD, Weissman NJ, Dilsizian V, Jacobs AK, Kaul S, Laskey WK, Pennell DJ, Rumberger JA, Ryan T, Verani MS, et al. Standardized myocardial segmentation and nomenclature for tomographic imaging of the heart a statement for healthcare professionals from the cardiac imaging committee of the council on clinical cardiology of the american heart association. Circulation 2002;105(4):539–542.