

# Three-Dimensional Apex-Seismocardiography

Samuel E Schmidt, Ask S Jensen, Jacob Melgaard, Claus Graff, John Hansen, Tanveer A Bhuiyan, Johannes J Struijk

Department of Health Science and Technology Aalborg University, Aalborg, Denmark

## Abstract

*Traditional apex-cardiography measures chest wall vibrations at the apex beat using an air-coupled microphone. To provide additional insight in apex-cardiography and chest vibrations we estimated the three dimensional displacement of the apex beat.*

*A 3-axis accelerometer was placed at the location of the apex beat in 5 healthy subjects in left lateral decubitus position. ECG, echo Doppler of the carotid artery and phonocardiography were recorded simultaneously. The 3D displacements of the apex beat were estimated by twofold integration of the accelerometer signal. The most dominating displacement direction was estimated as the largest eigen vector in a principal component analysis (PCA).*

*The peak-to-peak displacements in the longitudinal, transverse and perpendicular dimensions were  $0.39\pm 0.35$  mm,  $0.28\pm 0.15$  mm and  $0.38\pm 0.12$  mm (mean $\pm$ std). The dominating displacement direction changed largely from subject to subject, the average deviation from the downward perpendicular axis was  $3.8\pm 41$  degrees toward the superior direction and with  $18.4\pm 30$  degrees towards the medial line.*

*The longitudinal and transverse displacements show that single axis measurement along the perpendicular axis only reveals a part of the complex movements at the apex beat.*

## 1. Introduction

Apex-cardiography is measurement of chest wall vibrations at the apex beat [1]. Traditionally Apex-cardiography is obtained using an air-coupled microphone. The apex beat is a clinical marker, which can be palpated at the left 5th intercostal space, at the point of intersection with the left midclavicular line. Alterations, displacement or disappearance are indications of both cardiac and non-cardiac diseases, such as cardiomegaly, pulmonary diseases, shock and ventricular dysfunction.

Apex-cardiography is a member of the relative old

family of cardiac vibration quantification technologies like phonocardiography and Ballistocardiography, which all had their golden age before the emergence of echocardiography. However, modern electronics as microprocessors, tablets and advanced signal processing/classification might make these technologies very low cost and easy to use, which might spur new applications and revitalise these technologies [2-4].

Specific advantages of apex-cardiography compared to phonocardiography include its relation to left ventricular pressure and the possibility to identify the timing of aortic and mitral valve openings [5-6]. Modern applications of apex-cardiography might include screening for heart failure or quantification of ventricular synchrony.

To provide additional insight in the apex beat and apex-cardiography we estimated the three dimensional displacement of the apex beat using a 3-axis accelerometer. Compared to traditional Apex-cardiography Apex-Seismocardiography (aSCG) measures the chest wall acceleration and not a pressure wave in a closed air chamber.

## 2. Methods

3D apex beat displacement were estimated based on 3-axis accelerometer recordings of the apex beat.

### 2.1. Data acquisition

A custom-made 3-axis accelerometer was placed at the location of the apex beat in 5 healthy male subjects (Age: 27-42) lying in left lateral decubitus position. The location of the apex beat was identified using palpation of the area where the left 5th intercostal space intersects with the left midclavicular line. The point where the maximum beat was felt was chosen as the location of the apex beat.

Custom-made Cardiac lightweight (CLW) accelerometers where constructed using Silicon Designs accelerometers model 1221 (Silicon Designs Inc., Seattle, US) placed in a 3D printed housing, see figure 1. The weight of the packed accelerometers was 4 g. Three single-axis CLW accelerometers where glued together to

a 3-axis accelerometer. The CLW accelerometers were calibrated using a B&K vibration exciter and reference accelerometer (Brüel & Kjær, Nærum, Denmark).



Figure 1. The CLW accelerometer.

Phonocardiography from the fourth-left intercostal space and 3 lead ECG were recorded simultaneously with the accelerometer signals. The phonocardiography was recorded using an Acarix microphone (Acarix, Kgs. Lyngby, Denmark) [4]. The ECG, phonocardiography and accelerometer signals were recorded using an Iworx IX 228 data acquisition unit (iWorx Systems Inc., Washington, US). In three of the five subjects carotid artery flow was estimated using a Mindray M7 Doppler ultrasound scanner (Mindray, Shanghai, China).

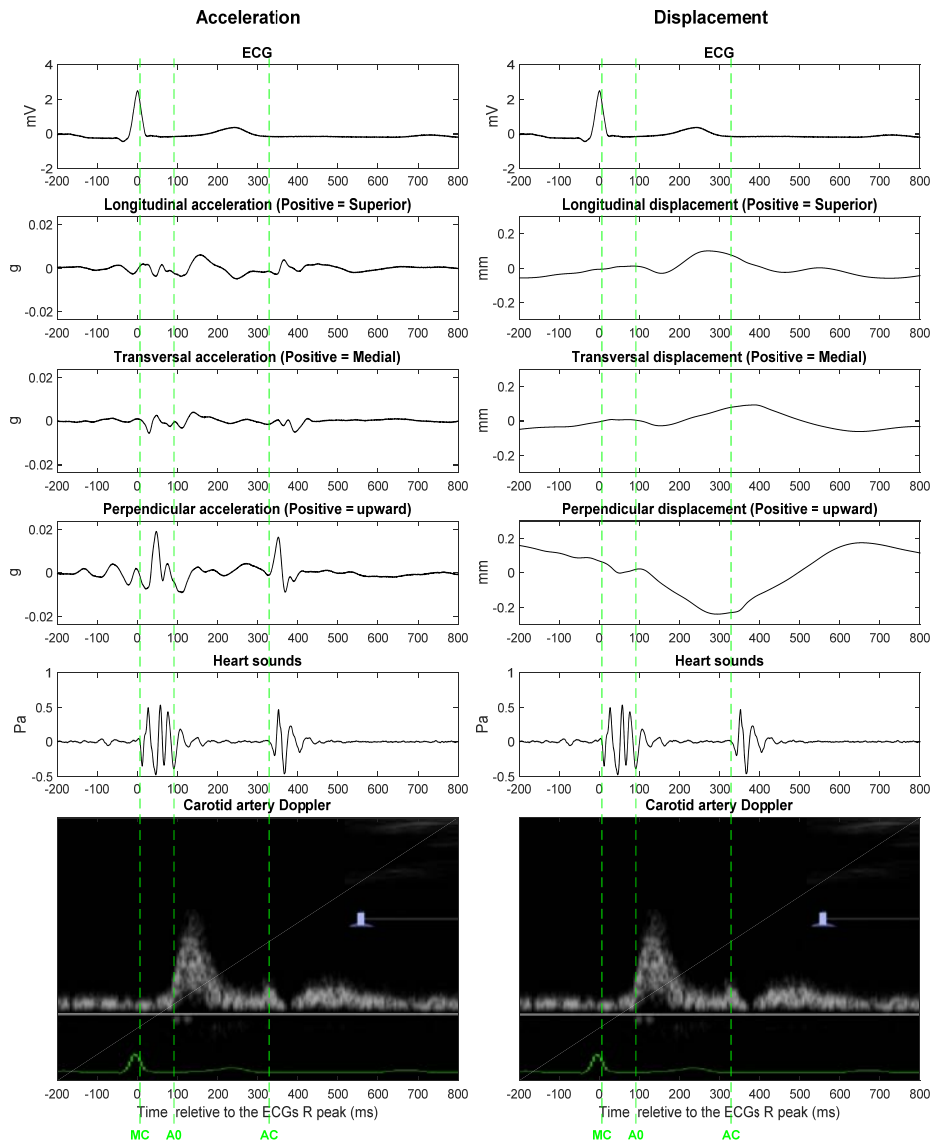


Figure 2. Left: Average beats of ECG, aSCG, heart sounds and a Doppler flow measurement of the carotid artery in subject 3. Closing of the mitral valve (MC) was defined as the onset of the first heart sound. The opening of the aortic valve (AO) was defined from the Doppler flow upstroke and the aortic valve closing (AC) as the onset of the second heart sound. Right: Similar to the left part of the figure, but with displacement estimates of the apex beat in three dimensions.

## 2.2. Signal processing

The 3D displacements of the apex beat were estimated by twofold integration of the accelerometer recordings and movements related to respiration were removed with a bi-directional high-pass filter. The cut-off frequency of

the high-pass filter was carefully chosen to 0.5 Hz. This removes the effect of respiration without effecting the aSCG wave. Using the ECG as a reference, 3D mean acceleration and displacement beats were constructed using an automatic segmentation algorithm similar to the one described in [8].

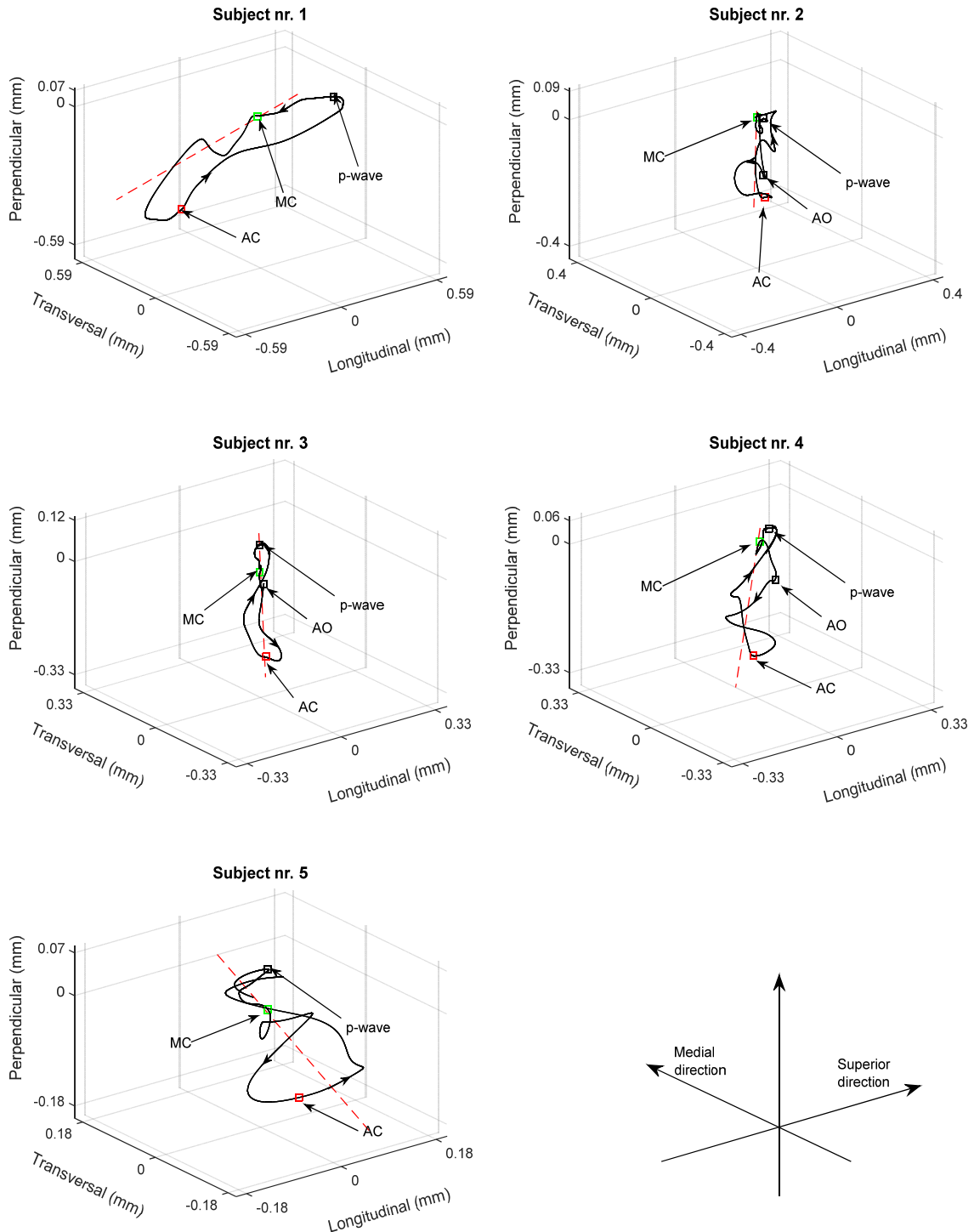


Figure 3. 3D plots of the apex beat displacements in the five subjects. The red dashed lines are the discretions of largest eigenvectors. The MC, AO and AC points were defined as in figure 2.

To determine the most dominating displacement direction principle component analysis (PCA) was conducted. The angles of the dominating displacement direction was estimated as the angle of the largest eigenvector.

### 3. Results

The mean acceleration beats from subject 3 are seen in left part of figure 2 and the mean displacement estimations for the subject are seen in right part of the figure.

The peak-to-peak displacements in the longitudinal, transverse and perpendicular dimensions were  $0.39\pm 0.35$  mm,  $0.28\pm 0.15$  mm and  $0.38\pm 0.12$  mm (mean $\pm$ std). The three dimensions displacements are seen in figure 3. A typical pattern was small downward or side ward movement in the isovolumetric contraction phase before a significant downward movement in the ejection phase, that was followed by an upward movement after closing of the aorta valves.

The dominating displacement direction changed largely from subject to subject, see the red dashed lines in figure 3. The average deviation from the downward perpendicular axis was  $3.8\pm 41$  (mean $\pm$ std) degrees toward the superior direction and with  $18.4\pm 30$  degrees towards the medial line. The variance of the 1st PCA component corresponded to  $85\pm 17\%$  of the total variance, indicating that the majority of movement occurs along a single direction, but this dimension is not necessarily perpendicular to the chest wall

### 4. Discussion

The longitudinal and transverse displacements show that single axis measurement along the perpendicular axis only reveals a part of the complex movements at the apex beat. This is further backed by the directions of 1<sup>st</sup> PCA components and the plots in figure 3. The large variation in the dominating direction might indicate different apex movement patterns, but might also indicate that the sensor placement differed from subject to subject. Therefore, a further challenge is to define a robust and standardized method for placement of the accelerometer. Compared to traditional apex-cardiography an upward slope in the early systole was not observed in the current recordings. This might be because the aSCG measures absolute acceleration/displacement compared to the pressure measured using the traditional air coupled microphone.

### 5. Conclusion

The movement of the chest wall at the apex beat follows a complex 3D curvature. The clinical relevance of the 3D curvature has to be investigated further.

### Acknowledgements

The authors thank Mr. Jan Stavnsbjerg for technical assistance in the development of the accelerometers.

### References

- [1] Ginn WM, Sherwin RW, Harrison WK, Baker BM. Apexcardiography: use in coronary heart disease and reproducibility. *American Heart Journal* 1967;73:168-80.
- [2] Wen YN, Lee APW, Fang F, Jin CN, Yu CM. Beyond auscultation: Acoustic cardiography in clinical practice. *International Journal of Cardiology* 2014;171:548-60.
- [3] Tavakolian KA, Dumont GA, Houlton GB, Blaber AP. Precordial vibrations provide noninvasive detection of early-stage haemorrhage. *Shock* 2014;41:91-96.
- [4] Schmidt SE, Holst-Hansen C, Graff C, Toft E, Struijk JJ. Detection of coronary artery disease with an electronic stethoscope. *Computers in Cardiology* 2007;34:757-60.
- [5] Martin CE, Shaver JA, Leonard JJ. Physical signs, apexcardiography, phonocardiography, and systolic time intervals in angina pectoris. *Circulation* 1972;46:1098-114.
- [6] Manolas J. Diastolic Handgrip Stress Test Using an External Pressure Transducer: on the road for a New Initial Screening Test for Preclinical Coronary Artery Disease?. *Journal of Cardiology and Therapy* 2014;1:102-107.
- [7] Zimmermann H, Hansen J, Schmidt SE, Hammershøj D, Møller H. Acoustic coupler for acquisition of coronary artery murmurs. *Computing in Cardiology* 2011;38:209-12.
- [8] Jensen AS, Schmidt SE, Struijk JJ, Hansen J, Graff C, Melgaard J, et al. Effects of Cardiac Resynchronization Therapy on the First Heart Sound Energy. *Computing in Cardiology* 2014.

Address for correspondence.

Samuel Emil Schmidt.  
Department of Health Science and Technology  
Aalborg University  
Fredrik Bajers Vej 7 C1-204  
9220 Aalborg Ø, Denmark.  
sschmidt@hst.aau.dk